

**ORTHOBIOLOGICS**  
**an OSSAP Monograph**

This book is dedicated to my parents Dr. S. Brahmanandam & Dr. I.A. Kanthamma  
and my Teacher Dr. G. Narasimha Reddy

- Dr. Amarnath Surath  
Chief Editor

Copyright © Orthopaedic Surgeons Society of Andhra Pradesh, 2019

Cover Design : Editorial Team

Typesetting & Printed at :

**Arudra Printing**

4/7 Brodipet, Guntur-2.

Ph : 9246767666

**This edition is for distribution by OSSAP and Janssen, Not for sale.**

## Contents...

---

I	Message from President	5
II	Message from Secretary	7
III	From the Editorial Team	9
IV	Contributors	11
V	Foreword	13
1.	Introduction to Orthobiologics	15
2.	BMPs in Orthopaedics	17
3.	Platelet biology and introduction of Platelet Rich Plasma	29
4.	Platelet Rich Plasma extraction with low cost assembled kit	37
5.	PRP in Tendinopathies	45
6.	PRP in OA Knee : Consensus Document	49
7.	Bone Marrow Aspirate Concentrate (BMAc)	53
8.	BMAc in Non union of Fractures	61
9.	Mesenchymal Stem Cells in Management of Avascular Necrosis Femur Head	69
10.	Orthobiologics in the treatment of Early Osteoarthritis - a Systematic Review	77
11.	Bibliography	89

## President's Message

*"it's what you think we know that keeps us from learning"*

- **Claude Bernard** (19<sup>th</sup> century French Physiologist)



Orthobiologics is a fascinating subject everybody thinks they already know and I am no exception. In the world of orthopaedics, replacing everything is an overwhelming practice. Regenerating biology is like a miracle. In the past it was too much to ask for and it was almost a weird thing. The dominance of industry and orthometallurgists has subdued any idea other than replacement.

But everything will fall or rise to its right place in time. At present, new in roads and new thought process have paved the way for use of biologics in medicine in general. Orthopaedics is one of the main branches of the medicine utilizing biologics to answer many unsolved questions .

We are bound to fail when you do not know for sure and do not know how to execute. This is where this monograph "ORTHOBIOLOGICS" will help in decision making and management. When we proposed the idea of bringing a monograph from OSSAP all fingers pointed to Professor Dr. Amarnath, the scientific orthopaedic surgeon from Guntur. Professor Amarnath and his team Dr.Dakshina Murthy, Dr.Ramireddy and Dr. Naresh Babu have unveiled a miracle (I feel Biologics is a miracle) for OSSAP .

As President of OSSAP, I am very fortunate to be associated with the team in bringing out the first monograph from OSSAP. All the members of OSSAP genuinely applaud the whole hearted efforts put in by the editorial team and authors of various chapters in the monograph.

I wish that the future administrative body of the OSSAP will continue this Academic feature.

**Dr. Y. Nageswara Rao**  
President, OSSAP

## **Greetings from the office of secretary of OSSAP**



It gives me immense pleasure to present before you “The OSSAP Monograph” series. The monograph on Orthobiologics”, is first of its kind from our state chapter. I take this opportunity to thank our Hon’ble President, Prof. Y Nageswara Rao for the initiation of OSSAP Monographs. I congratulate Prof. S. Amarnath (Editor in Chief), Sub-Editors and all authors of individual chapters for striving hard in bringing this extremely rare topic into existence.

Orthobiologics is in itself a complex topic in the post-graduation phase and with the advent of this book, post-graduates can get their basics right.

This Monograph comprises of interesting chapters like Bone Morphogenic Proteins and Platelet Rich Plasma, which are produced in a very logistical and economical manner. I would like to recommend this book for all the orthopaedic surgeons for updating their knowledge on Orthobiologics.

**Dr. Naresh Babu J**  
Secretary, OSSAP

## From the Editorial Team...



Dr. Amarnath Surath



Dr. Rami Reddy Mettu



Dr. AV Dakshina Murthy



Dr. J Naresh Babu

We wish to thank OSSAP for giving us the opportunity to compile the first monograph brought out by the association. Much thought has gone into selecting Orthobiologics as the topic since there are many lacunae in our knowledge regarding these substances. The line between proven methodologies and experimental work is blurred, hence we wish to set the record straight with this endeavour. Each chapter has been selected with care so that most of the clinically relevant aspects are covered.

The contributors were chosen based on their work in their respective fields and have divulged nuggets of information which will be helpful to all. This book will be of equal help to the practicing surgeon and post graduate student alike. Wherever needed technical details have been provided to initiate surgeons into the fascinating world of regenerative medicine. The team will be most gratified if some of the younger surgeons are stimulated to take up full time research into orthobiologics.

We wish that this monograph is followed by many more and hope the readers will find the book academically useful and reliable in clinical practice. Our heartfelt thanks to OSSAP president Dr. Y. Nageswara Rao and Secretary Dr. Naresh Babu for giving us this opportunity and Janssen for sponsoring the monograph.

**Dr Amarnath Surath**

**Dr AV Dakshina Murthy Dr Mettu Rami Reddy**

**Dr J Naresh Babu**

## Contributors...



**Dr. Amarnath Surath**

Prof. & HOD Department of Orthopaedics, NRI Medical College, Guntur.  
Amar Orthopaedic Hospital, Guntur  
e-mail : osteosan@yahoo.com; Mob : 9399962062



**Dr. J Naresh Babu**

Consultant Spine Surgeon, Mallika Spine Centre, Kothapet, Guntur.  
Secretary OSSAP  
e-mail : nareshspine@yahoo.com; Mob : 9989426898



**Dr. Arun Kumar Viswanadha**

Consultant Spine Surgeon, Mallika Spine Centre, Kothapet, Guntur.  
e-mail : drarunspine@gmail.com; Mob : 7660076007



**Dr. Rami Reddy Mettu**

Associate Prof. Department of Orthopaedics, NRI Medical College, Guntur.  
MGR Multispeciality Hospital, Guntur  
e-mail : ramireddy81@gmail.com; Mob : 9985314900



**Dr. AV Dakshina Murthy**

Orthopaedic Consultant, Guntur  
e-mail : orthomaths@yahoo.co.in; Mob : 9849127560

## Contributors...



### **Dr Vijay Shetty**

Consultant Orthopaedic Surgeon, Hiranandani Hospital, Mumbai. India  
Vice President, Indian Association of Sports Medicine  
Secretary, Indian Biologics Orthopaedics Society (IBOS)  
Associate Editor, SICOT World (open access) Journal, Examiner, SICOT International examinations, Member, Editorial Board, Hip International, Member, Editorial Board, Asian Journal of Arthroscopy  
e-mail : vijaydshetty@gmail.com; Mob : 9920707771



### **Dr. K Satya Kumar**

Prof. Department of Orthopaedics, NRI Medical College, Guntur.  
Orthocare, Vijayawada  
e-mail : kodurusk@gmail.com; Mob : 9000366555



### **Dr. Ramesh Sen**

Senior Director and Head of Department- Institute of Orthopedic Surgery  
Max Hospital, Mohali, Haryana.  
Ex-Prof. PGIMER Chandigarh.  
e-mail : info@drrameshshen.com; Mob : 9815856677



### **Dr. Karthik Pingle**

Consultant Orthopaedic Surgeon, Apollo Health City, Hyderabad.  
E-mail : pinglekarthik@yahoo.com; Mob : 9959020117

## Foreword



Thank you very much for asking me to write the foreword. The science of orthopaedics has had many twists and turns in my career spanning five decades. From initial conservative management to aggressive internal fixations, and now harnessing the body's internal mechanisms to repair itself from within is fascinating. This is the magical world of Orthobiologics.

The concept of this monograph is very thoughtful of OSSAP as this book provides a valuable single reference on this relatively new topic. I laud the efforts of the Executive body and the Editorial Team in bringing out this excellent book.

**Dr. C.K. Sarma, M.S.**

Rtd. Professor of Orthopaedics

## Introduction to Orthobiologics

**Dr. Amarnath Surath**

Orthobiologics are a group of substances found in the body which can help the process of healing or regeneration. They may be genes, proteins, cells or fully formed tissues. The beneficial effect may manifest in concentrations many times higher than found physiologically in the body. As a group, orthobiologics include Bone Morphogenetic Proteins ( BMP ), Growth Factors, Stem Cell Therapy, Synthetic Bone Graft and Allograft Tissue.

Every couple of decades brings to light a new paradigm in orthopaedic management. The seventies revolutionized fracture fixation by AO/ ASIF group, eighties saw phenomenal growth in arthroplasty and the millennium belongs to Regenerative Medicine of which Orthobiologics, form an integral part. The trend is to conserve biology and enhance tissue repair or regeneration by stimulating natural signaling mechanisms. The methodologies described herein are either specially developed molecules or cells whose numbers are increased many fold to have beneficial effects.

Bone Morphogenetic Proteins (BMP), discovered by Marshal Urist in 1965 were received with great enthusiasm due to their potential for osteoinductive potential. Proteins approved for clinical use are BMP-2 (Infuse ) and BMP-7 (OP-1). They are commercially synthesized by recombinant technology and are very expensive, which is why they are not in widespread use. Classic indications for BMP use are in management of open fractures, nonunion and spinal fusion.

Bone Marrow Aspirate Concentrate (BMAc) has gained popularity over the years due to the high concentration of stem cells and the regulatory issues surrounding the use of cultured stem cells. BMAc is autologous, implanted into site of pathology without any modification. The procedure is performed on site, which reduces potential complications such as contamination and infection. Common applications of BMAc are in the treatment of non union of fractures and avascular necrosis of femoral head.

Platelet Rich Plasma ( PRP ), has created a hype unparalleled in orthopaedic surgery. The reason for this meteoric rise in popularity is because it was endorsed by high profile sports persons as a “magic bullet” for musculoskeletal pathology. The other advantage of PRP is ease of administration as an out patient procedure. Many specialities have found a myriad of uses for PRP, such as dentistry, cosmetology, dermatology and ophthalmology. PRP as a single entity has managed to highlight the

importance of orthobiologics as a whole.

3D Tissue printing is the ultimate frontier of regenerative medicine. Imagine being able to design a whole organ or parts required, which can directly substitute damaged or diseased parts without risk of rejection or foreign body reaction. Achieving this feat will be an ode to the ingenuity of mankind and that can be made possible only by the use of Orthobiologics.

## BMPs in Orthopaedics

Dr. Naresh Babu J. & Dr. Arun Kumar Viswanadha

Bone Morphogenic Proteins (BMPs) are a group of molecules which induce mesenchymal stem cells to differentiate into bone forming cell lines that form new bone. They are a group of noncollagenous glycoproteins that mostly belong to the transforming growth factor-beta (TGF- $\beta$ ) superfamily. BMPs have been widely used in the field of orthopaedics since the last two decades. Marshall Urist in 1965 initially described the osteoinductive activity of BMPs. BMPs are a group of osteoinductive proteins that are usually extracted from bone matrix which are responsible for skeletal regeneration and bone healing. BMPs are capable of inhibiting chondrocyte differentiation independently and are recognised for their regulatory effects, especially in embryonic phase in the form of growth, differentiation and morphogenesis. The primary functions of BMPs are to activate inactive mesenchymal stem cells and to differentiate them into

osteoblast, chondroblasts and fibroblasts.

Apart from the above functions, BMPs are also involved in other physiological and pathological processes such as inflammatory response, bone formation and resorption, growth signalling pathways, oncogenesis and immune response. The safety and efficacy of BMP as bone graft substitute are influenced by its purity, local effects, systemic effects, immunogenicity and biocompatibility.

### Introduction

Bone ossification occurs through both intramembranous ossification and endochondral ossification.

*Intramembranous ossification* – Primitive mesenchymal stem cells (MSCs) are transformed into osteoprogenitor cells and then into osteoblasts which ultimately form the osteoid. It is typically seen in skull, mandible and clavicle bones.

Endochondral ossification – Here the mesenchymal stem cells transform into chondroblasts which lay down cartilage which later matures and degenerates. This degenerated cartilage is invaded by blood vessels and osteoblasts which finally lay down osteoid.

Both cellular events of intramembranous ossification and endochondral ossification involve MSCs which may be bone marrow derived or periosteum derived. These primitive MSCs are pluripotent progenitors that can differentiate into both osteoblasts and chondroblasts. This differentiation is regulated by molecules such as BMPs and Fibroblast growth factor (FGF).

Bone formation during developmental phase and fracture healing phase is governed by similar cellular and molecular events. Fracture healing requires adequate growth factors, sufficient bone matrix, good mechanical stability which altogether constitute appropriate cellular environment. When the process of fracture healing fails leading to non-union or delayed union, it requires

some stimulation for the process of bone formation. This can be achieved by biophysical methods such as ultrasound or biological interventions such as bone graft, bone marrow or biologically active molecules. Autogenous bone grafts are capable of stimulating bone formation through osteogenesis, osteoinduction and osteoconduction. Osteogenesis is the process of direct bone formation by the living osteoblasts present in the graft. Osteoinduction is defined as the ability of factors to induce osteogenesis in the extra osseous site. Osteoconduction is the process of allowing bone formation on its surface in order to promote bone growth. Autogenous bone graft from iliac crest is considered to be gold standard in the treatment of non-unions, delayed unions and bone defects. However, morbidity of graft site, limited availability of bone graft and variable success rates of union mandates the need for better options.

One of the effective methods of avoiding these complications arising from autogenous bone graft harvest is by the use of bone graft substitutes in the form of BMPs due to their osteoinductive properties.

### Structure

TGF- $\beta$  superfamily constitutes of various growth factors and differentiation factors, with BMPs forming the largest part in the family that also comprises of activins and inhibins. Currently there are more than 20 known BMPs and two commercially available BMPs - recombinant BMP-2(rhBMP-2) and recombinant BMP-7(rhBMP-7) approved by US FDA in 2004. In human bones, BMPs are secreted by osteoprogenitor cells, osteoblasts and platelets. BMPs are synthesized as inactive precursor proteins which contain propeptides and hydrophobic leader sequence. The active portion of BMPs is however located at the carboxy terminal of precursor molecule. This biologically active portion is released by proteolytic removal of signal peptide and propeptide. Active portions of all BMPs contain seven cysteine amino acid residues which are positioned similar to other members of TGF- superfamily. Of the seven cysteines, six form intramolecular disulphide bonds whereas seventh cysteine residue is involved in dimerization with another BMP monomer through a covalent

disulphide bond, resulting in a biologically active dimeric ligand for receptor activation. Overall the core structure of BMP dimers consists of “cysteine-knot” structure and is typically described as “wrist and knuckle” or “two bananas” shape.

BMPs, like any other TGF- $\beta$  family members elicit their effects through two types of serine-threonine kinase transmembrane receptors, type I and type II receptors. But unlike TGF- $\beta$ , BMPs are capable of binding to type I receptors even in the absence of type II receptors. However, their binding affinities increase when both type I and type II receptors are present

### Classification of BMPs

Till date more than 20 BMPs have been identified in vertebrates. Based on structural homology, BMPs can be further classified into several subgroups which includes BMP-2/-4 group, BMP-5/-6/-7/-8 group, BMP-9/-10 group and BMP-12/-13/-14 group. Among all BMPs, only BMP-1 has a metalloproteinase structure and acts as a carboxy terminal propeptidase for type I collagen. BMP family members are also identified in invertebrates such

as *Drosophila* decapentaplegic, 60A/glass bottom boat which are structurally similar to BMP-2/-4 and BMP -6/-7 respectively.

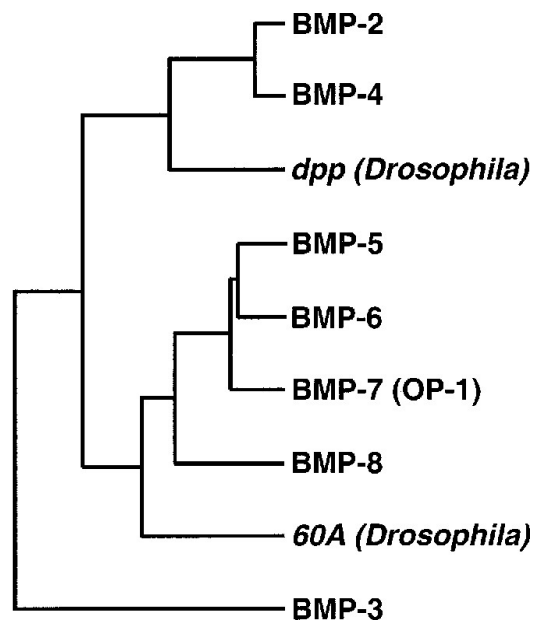


Figure 1 – Interrelations of BMP family. One subgroup consists of BMP-2, BMP-4 and *Drosophila* decapentaplegic(*dpp*). Other subgroup consists of human BMP-5, BMP-6, BMP-7, BMP-8 and *Drosophila* 60A.

### Functions of BMPs

The actions and functions of BMPs depend on various factors which are:

1. Type of target cell.
2. Maturation phase of target cells.
3. Local concentration of BMPs.
4. Other biological signals.

BMPs are mitogens (growth factors) that stimulate the production and multiplication of morphogens (differentiation factors) that transform connective tissue cells into osteoprogenitor cells. They play a pivotal role in embryonic development through specification of positional information in the embryo. They regulate growth, differentiation,

chemotaxis and apoptosis of cells such as epithelial, mesenchymal, haematopoietic and neuronal cells. Apart from inducing bone formation through intramembranous or endochondral ossification, they also induce osteoclasts leading to bone resorption. However, the local effects

of BMP are regulated by number of extracellular and intracellular antagonists (Table 1). Extracellular antagonists form complexes with BMP and prevent them from binding to their receptors whereas intracellular antagonists interfere with activation of R-Smads or facilitate their degradation.

Table 1 – Antagonists of BMPs

Extracellular antagonists	Intracellular antagonists
noggin	Smad6
chordin	Smad7
twisted gastrulation (Tsg)	Smad8b
gremlin	Smurf1
folistatin	Smurf2
BMPER	

### Carriers of BMPs

BMP is a water soluble molecule which diffuses into the body fluid easily. When administered alone, most of the protein molecule is lost rapidly due to diffusion and irrigation. To negate these effects and have a prolonged localised effect at target site, BMPs are administered in a carrier. Type I collagen is the most preferred carrier used for transport of BMPs. Type I

collagen can be extracted from bone or tendons, BMPs bind tightly to collagen extracted from bone and less tightly to collagen extracted from tendons. Also compression of collagen carrier leads to rapid release of BMPs, thereby the carrier is usually protected by a cage. Other carriers or delivery systems used previously in the literature are summarised in table 2.

Metallic implants	Ceramics	Natural Polymers	Synthetic polymers	Others
<ul style="list-style-type: none"> <li>▶ Anodic oxidized nanotubular Ti implant</li> <li>▶ Surface mineralized Ti6Al4V</li> <li>▶ rhBMP-2 and heparin immobilized Ti</li> <li>▶ BMP-2 incorporated on HA coated Ti surface</li> </ul>	<ul style="list-style-type: none"> <li>▶ HA Granules; 300-500 <math>\mu</math>m</li> <li>▶ <math>\beta</math>-TCP Granular implant (porosity: 75%, pore size: 50-350 <math>\mu</math>m)</li> <li>▶ Fibrous glass membrane</li> <li>▶ Mesoporous silica bio-glass scaffold</li> </ul>	<ul style="list-style-type: none"> <li>▶ Collagen</li> <li>▶ Gelatin</li> <li>▶ Chitosan</li> <li>▶ Keratin based</li> <li>▶ Hyaluronic acid</li> <li>▶ Silk based</li> </ul>	<ul style="list-style-type: none"> <li>▶ Polyethylene glycol</li> <li>▶ Polylactic acid</li> <li>▶ Poly (lactic-co-glycolic acid)</li> <li>▶ Poly <math>\epsilon</math>-caprolactone</li> </ul>	<ul style="list-style-type: none"> <li>▶ Composite materials</li> <li>▶ Stimulus responsive polymer</li> <li>▶ Stimulus responsive polymer</li> <li>▶ pH responsive polymer</li> </ul>

### Clinical Applications in Orthopaedics

BMPs are usually applied directly as an adjuvant therapy or as an alternative to autograft. However due to high costs being involved, its clinical usage has been limited. Currently, two commercial forms of BMPs are available for clinical usage – rhBMP-2 and rhBMP-7. While rhBMP-2 is FDA approved in 2002, while rhBMP-7

carries only humanitarian device exemption status.

#### 1. BMP as an alternative to autograft for non-unions

**Long Bones** – Currently, US Food and Drug Administration (FDA) approval of BMP use in long bones is limited to tibia non-unions as alternative to autograft. Many authors believe that despite the technical difference at different sites, non-union

is similar between upper and lower limbs. However, literature suggests that results with usage of BMPs in upper limbs has been poor. Apart from its usage in humerus pseudoarthrosis, BMPs have also been successfully used in few clinical situations involving clavicle and ulna.

Pseudoarthrosis of tibia remains to be the most frequent site of long bone non-union due to its poor muscular coverage, high incidence of open injuries and its anatomical peculiarity. Friedlaender et al initially reported the efficacy of BMP-7 in the treatment of tibia non-unions. Total of 124 tibia non-unions were treated with recombinant human osteogenic protein-1 (rhOP-1 or BMP-7) in a type I collagen carrier or by fresh bone autograft. According to them, 81% of OP-1/BMP-7 treated tibia non-unions and 85% of those receiving autogenous bone were successfully healed. They finally concluded that BMP-7 provided comparable results when compared with bone autograft, without donor site morbidity. This paper has reinforced interest in others and it has been accepted to be an alternative to autograft in long bone non-unions.

However, it is absolutely necessary to respect the classic principles of surgical treatment for pseudoarthrosis.

**Scaphoid** – Scaphoid is very commonly affected with non-union due to its precarious vascular supply. Bilic et al in a randomised control trial compared the efficacy of BMP-7 in the management of scaphoid non-unions. One group was treated by autograft alone, second by BMP-7, third by autograft with BMP-7 and fourth by allograft with BMP. Treatment included fixation with Herbert Screw and plaster cast for 1 month. Patients treated with autograft and BMP-7 healed successfully within 3 months whereas other groups required 9 months. However, all the evidences on scaphoid non-unions were poor.

## **2. BMP as an alternative to autograft for fusion**

**Foot and ankle** – Few authors have used BMPs to improve the rates of union in ankle arthrodesis for patients with comorbidities affecting bony union. Most publications deal with different types of arthrodesis performed in complex cases. Initially use of BMP in complex foot and ankle

arthrodesis seem to be a safe option considering its high failure rates. However, there is no randomised control trial available till date to give a suggestable conclusion.

## Spine

By far, spine is the most common site associated with BMP application. US FDA has approved the usage of rhBMP-2 in anterior lumbar interbody fusions. However recent studies have shown that BMP use has been extended to fusions performed with other approaches as well.

### **Studies leading to US FDA approval of rhBMP-2 in Spine Surgery**

After conducting various animal trials, Boden et al in the year 2000 first published a randomised control trial with usage of rhBMP- 2/collagen sponge as a substitute for autologous bone graft for anterior lumbar interbody fusion (ALIF). They reported that spinal fusion was equally reliable with usage of rhBMP-2 when compared with iliac crest autograft without any adverse effects. In 2002, Boden et al reported a second study on rhBMP-2 where they demonstrated consistent

radiographic fusion rates who underwent posterolateral fusion with or without internal fixation. In the time span of 10 years, a total of 13 industrial sponsored trials were published which evaluated the efficacy and safety of rhBMP-2 in lumbar and cervical spine surgery. Total of 1580 patients were enrolled in all studies (780 – rhBMP-2 group and 800 – control group). In the initial trials, rhBMP-2 was administered in two different preparations;

InFUSE (Medtronic Sofamor Danek, Memphis, TN) – 1.5mg/mL of rhBMP-2

AMPLIFY (Medtronic Sofamor Danek, Memphis, TN) – 2mg/mL of rhBMP-2

All these human studies recommended the clinical application of BMPs in spine surgery. They reported more than 95% fusion rates at last follow up across all fusion techniques. They further stated that rhBMP-2 was superior or equally effective to iliac crest autograft in terms of clinical outcomes without any adverse effects.

Based on these clinical studies,

US FDA finally approved InFUSE (Medtronic Sofamor Danek, Memphis, TN) in the year 2002 as a bone graft substitute for a single level ALIF between L4-S1 within a specific LT-cage (LT-CAGE; Medtronic Sofamor Danek, Memphis, TN). Initially described as an adjuvant for spinal arthrodesis more widespread usage of InFUSE has been documented in the last decade. In USA, usage of InFUSE has increased from 0.7% in 2002 to 25% in 2006. By the end of 2007, 50% of all primary anterior lumbar interbody fusions, 43% of posterior/transforaminal lumbar interbody fusions, 30% of posterolateral fusions were reported with InFUSE. However more than 85% of its utilisation was accounted for off-label administration.

### **Controversy with BMPs in Spine Surgery:**

Not a single adverse effect was reported in the 13 industry sponsored trials which were published in many reputed journals. The estimated risk of rhBMP-2 usage has been less than 0.5% which is far inferior to commonly used analgesics and antibiotics. These trials also reported high rates of morbidity (40%-60%) with iliac crest

bone graft harvest. However, several independent studies started reporting serious complications with rhBMP-2 usage from the year 2006 with adverse effects ranging from 20% to 70%. These complications include heterotopic ossification, increased infection rates, formation of seroma/haematoma, dysphagia, difficulties in post-operative airway maintenance, increased incidence of neurological deficits, increased post-operative pains, retrograde ejaculation and malignancy (Table 3). In particular, there has been increased association between retropharyngeal edema and rhBMP-2 which led to difficulties with airway maintenance. Such reports have mandated US FDA to issue a public health notification concluding that safety and efficacy of rhBMP-2 in cervical spine was not established.

Following this public health notification, Federal Government launched an investigation into the reported off-label usage of InFUSE and claims of illegal marketing by Medtronic which includes "payments to doctors in form of cash/gifts to use of InFUSE". In 2011, Carragge et al compared the efficacy reports of rhBMP-2 documented in original industry trials

with FDA data summaries, follow up studies and administrative databases. They concluded that adverse reactions in patients receiving rhBMP-2 was 10 to 50 folds higher than originally reported. They also commented that significant financial relationship exists between authors of 13 original FDA trails and Medtronic company (Total

sum involved - \$12,000,000 to \$16,000,000; Range - \$560,000–\$23,500,000 per study). For studies reporting on 20 or more patients with usage of rhBMP-2, at least one author received \$1,000,000. Whereas if the study includes more than 100 patients, amount increased to \$10,000,000.

**Table 3 - List of potential adverse events associated with the use of INFUSE Bone Graft/LT-Cage Device**

- ▶ Bone fracture
- ▶ Bowel or bladder problems
- ▶ Cessation of any potential growth of the operated portion of the spine
- ▶ Change in mental status
- ▶ Damage to blood vessels and cardiovascular system compromise
- ▶ Damage to internal organs and connective tissue
- ▶ Death
- ▶ Development of respiratory problems
- ▶ Disassembly, bending, breakage, loosening, and/or migration of components
- ▶ Dural tears
- ▶ Ectopic and/or exuberant bone growth
- ▶ Fetal development complications
- ▶ Foreign body (allergic) reaction
- ▶ Gastrointestinal complications
- ▶ Incisional complications
- ▶ Infection
- ▶ Insufflation complications
- ▶ Loss of spinal mobility or function
- ▶ Neurological system compromise
- ▶ Nonunion (Pseudarthrosis), delayed union, mal-union
- ▶ Postoperative change in spine curvature, loss of correction, height, and/or reduction
- ▶ Retrograde ejaculation
- ▶ Scar formation
- ▶ Tissue or nerve damage

### 3. BMPs in experimental phase

Besides all the above clinical applications, experimental studies are undergoing with usage BMPs in cartilage repair. Many authors believe that use of BMPs in paediatric

population is contraindicated. However, few studies are in experimental phase with use of BMPs in conditions like congenital pseudoarthrosis of tibia and Legg Calve Perthes disease.

### Conclusion

The accumulation of data on BMP's provides a number of key lessons to orthopaedic surgeons. Firstly, use of BMP's has been associated with high fusion rates, both in non-union of tibia and in spinal arthrodesis. However, with bone graft harvested from iliac crest still being considered as gold standard for achieving union in long bones and with local graft obtained being sufficient for arthrodesis in spine surgery, usage of BMP's is being limited in today's practice. Secondly, surgeons should be aware of devastating complications which can be encountered with irresponsible usage of BMP's. Finally, the orthopaedic community and patients must remain informed about the profile of these BMP's which can offer benefits when used cautiously and responsibly.



## Platelet biology and introduction to Platelet Rich Plasma

Dr. Rami Reddy Mettu

### Biology of Platelets

Platelets were initially discovered by Giulio Bizzozero in the year 1882. For many decades, the dynamic and multifunctional nature of platelets remained a field of interest mostly for biologists and not clinicians. Although very dynamic in functional activity, they usually prefer to remain in inactive state and get activated only when a blood vessel is damaged or injured. Haemostasis is not the sole function of platelets, they possess several multifunctional attributes monitoring the homeostasis of the body.

Platelets develop from megakaryocytes in the marrow. Each megakaryocyte can produce 5000-10000 platelets. Approximately  $\frac{2}{3}$ <sup>rd</sup> of the platelets circulate in the blood and  $\frac{1}{3}$ <sup>rd</sup> are stored in the spleen. An average healthy adult can produce  $10^{11}$  platelets per day. The normal platelet count is  $(150-400) \times 10^3$  per microliter of blood. The diameter of a mature platelet is 2-3  $\mu$ m. Platelets usually remain alive for 5-11 days. Old platelets are destroyed by phagocytosis in the spleen and liver by Kupffer cells.

Platelets are unique in their structural assembly. Though they are

a nucleate, they have distinct mitochondria, plasma membrane composed of phospholipid bilayer. This is the site of expression of various surface receptors and lipid rafts which helps in signalling and intracellular trafficking.

Platelets contain huge number of biologically active molecules within cytoplasmic granules namely alpha granules ( $\alpha$ ), dense granules ( $\delta$ ) and lysosomes ( $\lambda$ ). The contents of these granules are released when platelets are activated during vessel injury and thus play an important role in haemostasis, inflammation, wound repair and also in pathological process of atherosclerosis. Each formed platelet contains about 50-80  $\alpha$ -granules. These  $\alpha$ -granules contain more than 30 adhesive proteins including platelet derived growth factor (PDGF), transforming growth factor ( $TGF\beta$ ,  $\beta 1$  and  $\beta 2$  isomers), platelet factor 4 (PF4), interleukin 1 (IL1), platelet-derived angiogenesis factor (PDAF), vascular endothelial growth factor (VEGF), epidermal growth factor (EGF), platelet-derived endothelial growth factor (PDEGF), epithelial cell growth factor (ECGF), insulin like growth factor (IGF) etc.

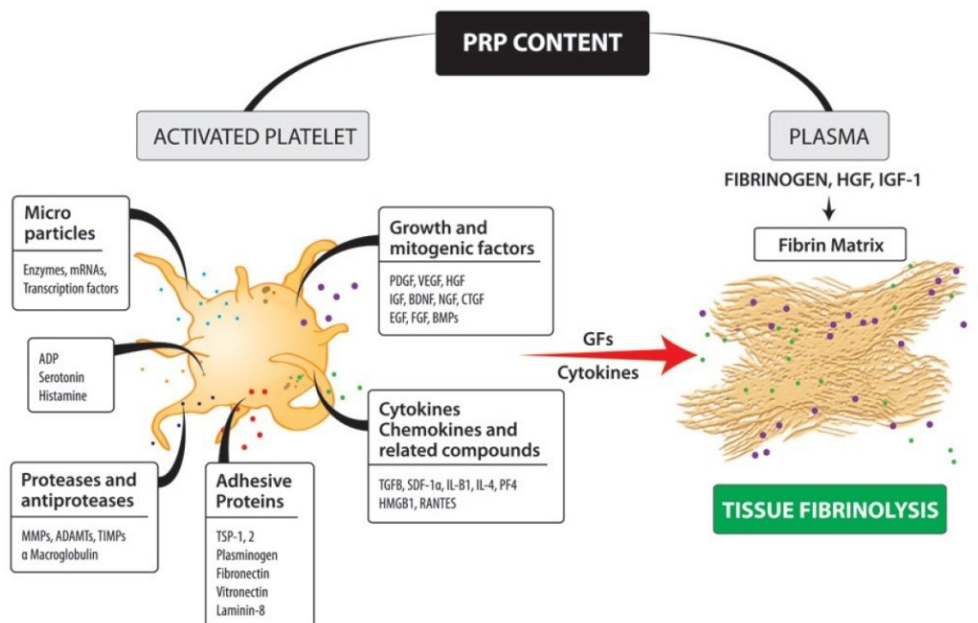


Figure 1: Biology factors in Platelet Rich Plasma.( courtesy of mikel sanchez et al.)

## Platelet Rich Plasma

By definition, Platelet Rich Plasma (PRP) must contain a higher concentration of platelets than baseline. To be labeled as PRP, a platelet count of 3-5 times of the baseline should be present in the platelet concentrate (many studies like Max et al mention the platelet count 1 million as standard value for PRP).

The properties of PRP are based on the production and release of the factors when the platelets are activated. **Platelets begin secreting these proteins within 10 minutes of activation. After initial release of growth factors, the platelets synthesize and secrete additional factors for the remaining days of their life span.**

The rationale for use of PRP is based on their capacity to supply and release supraphysiologic amounts of essential growth factors and cytokines from their alpha granules to provide a regenerative stimulus that augments healing and promotes repair in tissues with low healing potential (Table 1).

**Table 1: Growth Factors in Platelet Alpha granules and its function**

<b>GROWTH FACTORS</b>	<b>FUNCTIONS</b>
PDGF	Stimulates cell proliferation Chemotaxis Stimulates angiogenesis
TGF- $\beta$	Stimulates production of collagen type I and type III Angiogenesis Re-epithelialization Prevents collagen break down
VEGF	Stimulates angiogenesis
EGF	Influences cell proliferation and cytoprotection Accelerates re-epithelialization Increases tensile strength in wounds Facilitates organization of granulation tissue
b-FGF	Stimulates angiogenesis Promotes stem cell differentiation and cell proliferation Promotes collagen production and tissue repair
IGF-1	Regulates cell proliferation and differentiation Influences matrix secretion from osteoblasts Production of proteoglycan, collagen, and other noncollagen proteins

### Components of Platelet Rich Plasma

#### 1. Platelets

Although platelets play a key role in haemostasis, they are central in mediating the anabolic effects of PRP

by virtue of releasing growth factors stored in their alpha granules. During the initial phases of wound repair, activated platelets attract and foster cell migration into the wound by aggregating and forming a fibrin matrix. This matrix then serves as a tissue

scaffold for sustained release of platelet growth factors and cytokines, which stimulate cell recruitment, differentiation, and communication.

## 2. Leukocytes

Leukocytes are essential mediators of the inflammatory response, host defence against infectious agents, and wound healing. Neutrophils are involved in the inflammation phase of wound healing. Monocytes and macrophages facilitate tissue repair by debriding and phagocytising damaged tissue and debris. Similar to platelets, macrophages also secrete growth factors that are important in tissue repair and have been shown to contribute to subchondral bone regeneration.

## 3. Red blood cells

Red blood cells (RBC) content is

typically reduced or absent in PRP because of the centrifugation process. Destructive process is thought to occur in human synoviocytes treated with RBC concentrates, leading to significantly greater cell death and cartilage degradation.

### Classification of PRP

Dohan et al in the year 2009 classified PRP based on presence of leukocytes and density of fibrin network (Table 2). Mishra et al in the year 2012 proposed a classification system which is based on platelet count, activation and leukocytes for clinical application in Sports medicine (Table 3). Another classification system similar to Mishra et al classification is called “PAW Classification” (Platelets, Activation, White cells). However, Dohan's classification is still being widely used till date.

Table2: Dohan's classification of PRP

P-PRP	Pure Platelet-Rich Plasma Or Leukocyte - Poor Platelet - Rich Plasma	without leukocytes and with a low-density fibrin network after activation
L-PRP	Leukocyte-and Platelet-Rich Plasma	leukocytes and with a low-density fibrin network
P-PRF	Pure Platelet-Rich Fibrin	without leukocytes and with a high-density fibrin network
L-PRF	Leukocyte- and Platelet- Rich Fibrin	leukocytes and with a high-density fibrin network

Table 3: Mishra's Classification of PRP for application in Sports medicine.

Types		White blood cells	Activation of PRP
Type 1 (A/B)	L-PRP solution	increased	No activation
Type 2 (A/B)	L-PRP gel	increased	activated
Type 3(A/B)	P-PRP solution	Minimal or absent	No activation
Type 4(A/B)	P-PRP gel	Minimal or absent	activated

*L-PRP: Leukocyte rich platelet rich plasma, P-PRP- leukocyte poor plasma*

*NOTE: Subtype A – Platelet concentrations >5 ´ patients baseline. Subtype B – Platelet concentrations <5 ´ patients baseline.*

Sports medicine platelet rich classification system sub divided PRP type into A&B depending on whether the platelet concentration is more than 5X patients baseline (A) or less than 5X patients baseline (B). This sub classification is weakened by the fact that the serum can influence the final platelet count.

## PRP Applications

### 1. Wound Healing

In general, wound healing can be separated into 3 phases namely Inflammation, Proliferation and Remodeling. The initial inflammation phase is characterized by haemostasis, with platelets establishing clot formation, and the

release of growth factors that aid in activating and attracting inflammatory cells like neutrophils and macrophages to the site of injury. The proliferation phase is characterized by the construction of an extracellular matrix associated with granulation, contraction, and epithelialization. Remodelling phase is associated with production of collagen and scar tissue.

The physiologic progression through these phases of wound healing is orchestrated by growth factors and cytokines, many of which are released and modulated by components in PRP.

### 2. Rotator cuff tears

Degenerative changes are

expected to be the cause of cuff tear, in the older population, There are chances that a meticulously performed rotator cuff repair may fail or heal sub optimally. It is important to note that the distal part of the rotator tendon has inherently poor healing capabilities. Here PRP with its growth factors may thus be an attractive option for the stimulation of tendon healing.

Randelli et al. were the first to conduct an uncontrolled pilot study of PRP augmentation along with arthroscopic rotator cuff repair. Their reports showed statistically significant improvements in VAS, constant and UCLA shoulder scores compared to preoperative values.

Rha et al. compared ultrasound guided PRP injection with dry needling and concluded that autologous PRP injections lead to a progressive reduction in the pain and disability when compared to dry needling.

However, results of PRP use in various studies are quite different .Thus evidences available so far do not provide a clear picture regarding the use of PRP in rotator cuff tears.

However, PRP may be used in rotator cuff injuries either as an adjunct

to surgery, or as stand alone injections. But prior explanation to the patient about the prognosis and the limited available evidences will be healthy.

### **3. *Tendoachilles tears***

Tendinopathies and tears of achilles tendon are notorious for non healing. PRP use has been attempted for enhancing healing at this site.

DeJonge et al. in a study of chronic tendinopathy (7 cm proximal to the Achilles tendon insertion) injected PRP or saline at that site .After the procedure they subjected the patients to an eccentric training program.

One year of follow up showed no clinical and ultra sonographic superiority of PRP injection over the placebo injection.

Owens et al. reported modest improvement in functional outcome in patients who had received PRP injection for mid substance Achilles tendinopathy Monto et al. reported clinical success in resistant Achilles tendinosis. The improvement noted was in the AOFAS score.

Enhancement of repair of the Achilles tendon tear with PRP has also

been attempted. Sanchez et al showed better results with TA repair with augmented with PRP in sports people. In summary, the results of use of PRP in Achilles Tendonopathy are superior to their use in complete tear of the tendon.

#### **4. ACL reconstruction**

#### **5. Subacromial impingement**

#### **6. Shoulder osteoarthritis**

#### **7. Osteoarthritis knee**

Growth factors in the alpha granules have been postulated to be chondroprotective and capable of improving the physiology in osteoarthritic joints. Spaková et al. conducted a RCT on 120 patients with Kellgren and Lawrence Grades 1, 2, or 3 Osteoarthritis, comparing PRP injection with hyaluronic acid and concluded that autologous PRP was an effective and safe method in the treatment of the initial stages of knee osteoarthritis. Patel et al. published the results of a randomised control trial conducted on 78 patients (156 knees) with bilateral osteoarthritis and reported improvement VAS scores for pain and in all parameters of WOMAC scores in patients who received PRP injections.

Osteoarthritis of the knee is one of the commonest degenerative diseases encountered in clinical practice and the prospect of arresting the disease process in its initial stages looks rewarding. The clinical evidences of PRP use in early knee osteoarthritis weighs in favour of PRP.

#### **8. Plantar fasciitis**

Shetty et al found no difference in effectiveness of platelet-rich plasma and corticosteroid injections at 6 months of follow-up.

Wilson et al in his one year follow up study of showed PRP is more effective than cortico-steroids .

Based on above studies it is obvious using PRP in Chronic Plantar Fasciitis requires more evaluation

However it can be tried as an alternative to corticosteroids.

#### **9. Lateral epicondylitis**

This condition can potentially be handled well with conventional methods. However a significant number of patients do become resistant; PRP has significant benefit in this patients.

Mishra and Pavelko were the first

to use PRP injection for such resistant lateral epicondylitis. Their pilot study showed good results in terms of pain relief and functional improvement. Peerbooms et al. in his RCT with 100 patients, reported better improvement over the period of one year in the management of Lateral epicondylitis with PRP than management with steroids. Chaudhary et al. used ultrasonographic guidance for injection and noticed a trend towards an increase in the vascularity at the musculotendinous junction of the extensor tendons.

With available evidences PRP injection is the treatment of choice, instead of a corticosteroid injection in patients with failed conventional methods.

### **10. Patellar tendinosis**

Jumper's knee in athletes is a common cause of knee pain. Filardo et

al. evaluated the efficacy of PRP injections for refractory patellar tendinopathy and concluded that PRP injections have the potential to promote the achievement of a satisfactory clinical outcome, even in chronic refractory tendinopathy.

### **11. Nonunion of bones**

Fracture healing is a process affected by many factors. Although PRP has been reported in literature to be a biological treatment which increases healing, Sayetal reported adequate healing was not achieved in the treatment of non-union with PRP injection. However, in selected patients with delayed union, PRP injection can be recommended in non-surgical treatment. Sebastian Lippross in his hypothesis opines that PRP can be a supportive procedure in non-union, if used in the right manner.

## Platelet Rich Plasma extraction with low cost assembled kit

Dr. Amarnath Surath, Dr. Rami Reddy Mettu & Dr. N. Suresh Prasad Reddy

### Introduction

Platelet-rich plasma (PRP) is defined as the plasma fraction derived from autologous blood having a platelet concentration approximately five times above baseline. It is classified as an “Orthobiologic”; a substance that enhances the body’s innate ability to repair and regenerate. PRP therapy has lately gained attention as a safe, nonsurgical, biological treatment of osteoarthritis and a wide variety of musculo skeletal conditions. At present there is lack of data available to confirm that PRP works as postulated. Future large randomized controlled trials (RCTs) are needed to assess its efficacy. The present study has used the gravitational platelet sequestration ( GPS ) technique to concentrate platelets. We have designed a low cost kit by modifying readily available consumables and a table top laboratory centrifuge. After reviewing the existing literature the parameters for centrifugation were determined to produce a platelet count close to one million. These kits provide PRP at economic price so as to make

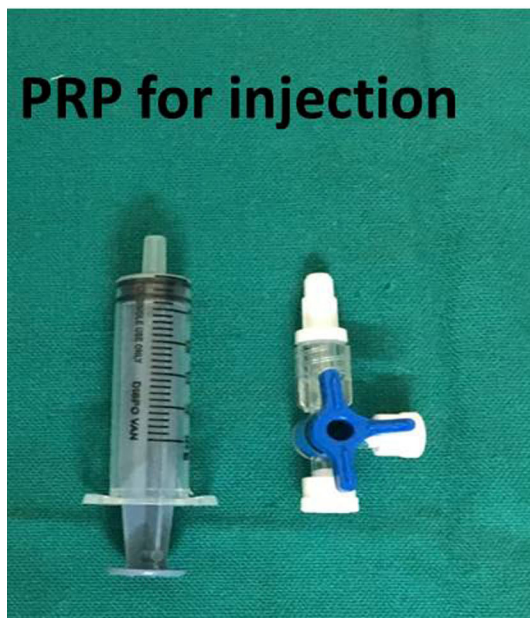
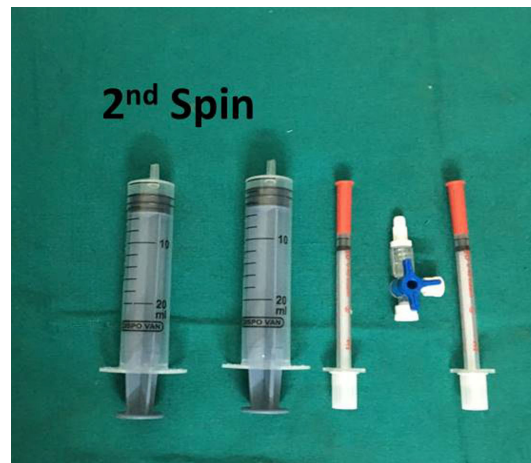
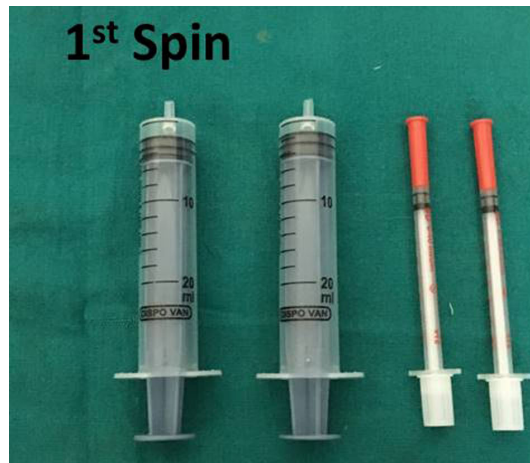
large scale clinical trials possible.

### Materials and methods

A total of 150 volunteers were selected as test subjects on whom PRP extraction was performed. Those with platelet count less than two lakhs and suffering from infective or connective tissue pathology were excluded from study. This study was approved by institutional ethics committee and informed consent taken from all volunteers. Two spin technique was used to extract PRP.

### Equipment required for processing 40ml venous blood (figure1)

1. Centrifuge (Remi R-4C), 4000rpm with countdown timer fixed angle rotor, capacity 4x50 ml
2. First centrifugation (soft spin) : 2x20cc syringe, 6ml ACD-A (Acid citrate dextrose), 2xBD insulin syringe
3. Second centrifugation (hard spin): 20cc syringe, 3-way cannula, BD insulin syringe
4. PRP extraction: 10cc syringe, 3-way cannula.



### Procedure

#### Step I :

Three ml ACD-A was taken in 20ml syringe and 17 ml blood drawn from the ante cubital vein. Blood (0.3 ml) was sent for initial platelet

Figure 1:  
Consumables required for PRP  
extraction.

count.(figure2) Nozzle of the syringe was blocked firmly with the cap of the insulin syringe. With a heavy scissors flanges on the either side of the syringe barrel were cut.( Figure 3) The piston was cut leaving one inch projecting out of the barrel. The two syringes were placed in centrifugation tubes opposite to each other with the tip pointing upwards. This will help balance the centrifuge and minimize vibration. (Figure 4) The first spin was set at 1500rpm for 15mins without brake (Soft spin).

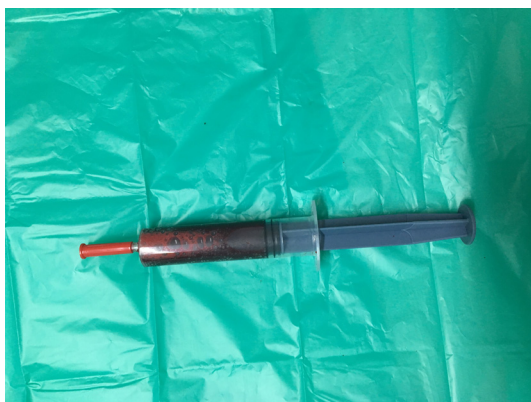

Figure 2: 20cc syringe with 3ml of ACD-A and 17ml whole blood.

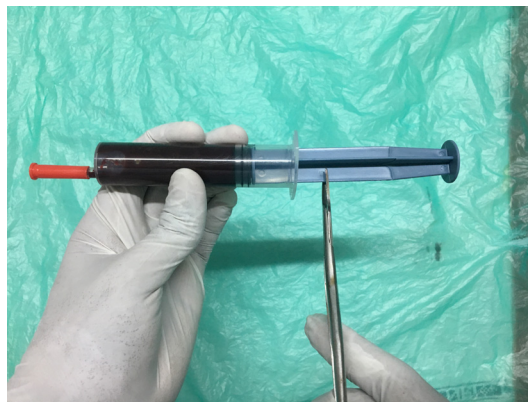


Figure 3: Modifying syringe to fit into centrifuge rotor.




Figure 4: Lab centrifuge.

## Step II

After soft spin blood in the syringe was separated into three layers. The bottom layer comprises of RBC, the middle layer leucocytes and the top layer, plasma with platelets in suspension. (figure 5) The serum was drawn into the second 20cc syringe through the 3-way cannula. Care was taken to avoid aspiration of the buffy

coat and RBC. ( Figure 6) The combined volume of plasma from both syringes ranged between 16-18ml. The syringe was again capped and modified to fit the centrifugation tube. A counter weight having an equal volume of saline was placed in the opposite tube for balance. ( Figure 7) The second spin was set at 3500rpm for 7minutes (Hard spin).

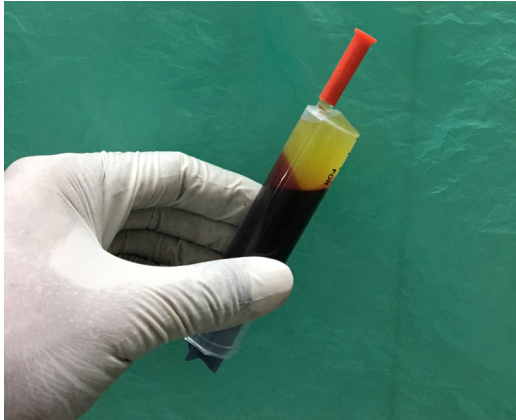


Figure 5: Appearance after soft spin [1500RPM for 15 minutes].

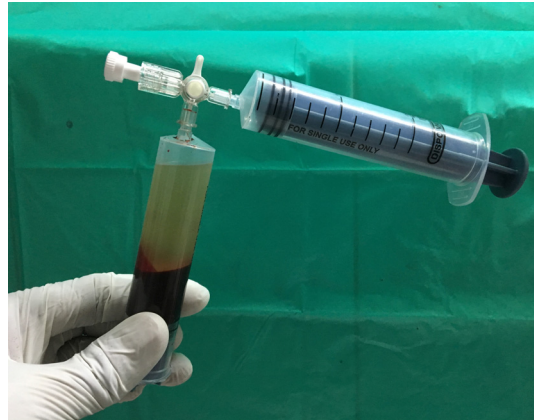

Figure 6: Aspirating serum into second syringe after soft spin.



Figure 7: Syringe prepared for second spin along with counter weight.

### Step III

At the end of second spin the syringe contains Platelet Poor Plasma (PPP) on top and platelets along with scanty WBC at the bottom in the form of a pellet. (Figure 8) The supernatant plasma is drawn and discarded leaving about four ml at the bottom which is reconstituted to form PRP fraction. This is sent for culture and counts.

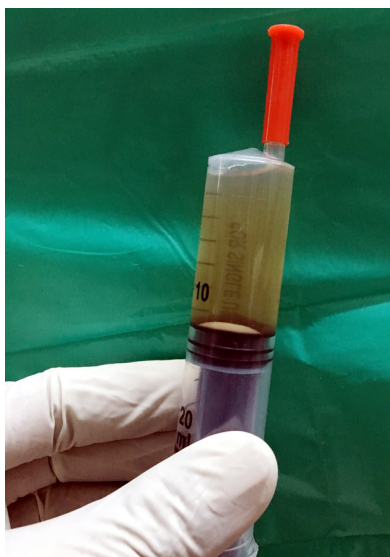


Figure 8: Appearance of syringe after second spin.

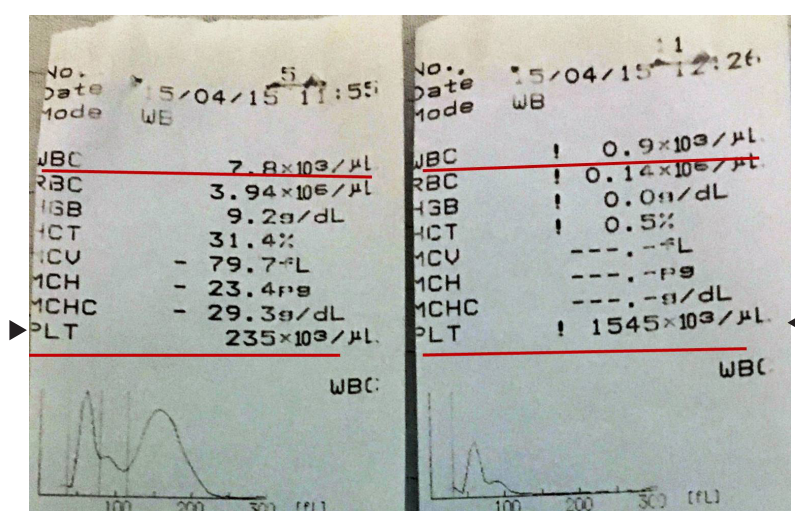


Figure 9: Typical blood counts from peripheral blood and PRP sample showing baseline platelet count of 2.35 lacs increased to 15.45 lacs after concentration.

## Results

PRP was extracted from 150 samples and the results are tabulated in Table 1. The Average Platelet count from peripheral venous blood was  $259 \times 10^3/\mu\text{L}$  (range from  $211 \times 10^3$  to

$427 \times 10^3/\mu\text{L}$ ). Average platelet counts after concentration were  $1743 \times 10^3/\mu\text{L}$  (range  $810 \times 10^3$  to  $2700 \times 10^3/\mu\text{L}$ ). (chart1). Only three patients had values below one million which was due to blood leak from the syringe during centrifugation. Platelet counts in

excess of 1million/ $\mu$ L were obtained in 147 (98 %) which validates the methodology. The amplification of platelet count ranged from 5-7x. All the samples were sent for culture and sensitivity studies and none of them

showed bacterial contamination. This validates the technique as sterile and safe for clinical application. Statically analysis shown in table 2 proved to highly significant.

Table 1: Showing platelet counts before and after PRP extraction.

Pherperial blood platelet count	No of persons	Platelet count in PRP extract	No of persons
2 to 2.5 lakhs	98	6 to 10 lakhs	5
2.5to 3 lakhs	21	10 to 12 lakhs	34
3 to 3.5 lakhs	14	12to 15lakhs	17
3.5 to 4 lakhs	10	15 lakhs and above	93
4to 4.5 lakhs	7		

## Discussion

A number of devices are available in the market which extract PRP utilizing single or double spin techniques. Whatever the equipment used, the concentrations of platelets should be at least 1,000,000/ $\mu$ l in order to have therapeutic effect. High cost of equipment has deterred most surgeons from using the kits frequently. This study made use of readily available consumables which are sterile and pyrogen free. We avoided the use of centrifugation tubes as they are meant for laboratory use and might not be pyrogen free. This is a low cost

kit compared to commercially available equipment [ Rs:350]. All samples were sent for culture and sensitivity studies and returned sterile. Potential contamination was avoided as it was a closed loop procedure performed at point-of-care. The choice of anticoagulant was between heparin and ACD-A. Initial trials were done with heparin which failed to return adequate platelet counts hence we shifted to ACD-A. Slichter and Harker stated that ACD-A maintains intra platelet signaling thus improving the responsiveness of platelets. Venous blood was drawn with a 21G

hypodermic or butterfly needle to prevent inadvertent activation of platelets. The butterfly needle was used when more than one syringe of peripheral blood was needed. The use of ACD-A resulted in better platelet counts but no attempt was made to test their viability. Platelet counts were performed on the peripheral blood sample and the PRP sample employing automated cell counter (Sysmex KX-21N). We did not manually count the platelets although published studies mention that the variation between automated and manual counting was only 1.1%. The PRP was leucocyte depleted because meticulous care was taken to avoid the buffy coat after the first spin. Schneider and Tiidus have stated that the presence of leucocytes might exacerbate existing tissue damage. A peripheral blood volume of 20-40ml produced 2-4ml of PRP which is ready for injection. Activation of the platelet concentrate is beyond the scope of this study as it describes only platelet

extraction procedure and not clinical applications. Calcium chloride added to PRP in a ratio of 1:10 is a potent activator, however the presence of collagen as in tendinopathy and diabetic wounds serves to activate platelets. Once activated 95% growth factors are released within one hour but secretion continues through the lifespan of the platelet. Fukaya et al have used similar methodology and achieved platelet counts in excess of six million. This study was performed on two volunteers only and utilized eight syringes which increases the chances of contamination. Many published articles state that very high platelet counts may have an inhibitory effect, hence the question, "How much is too much?", remains unanswered. One limiting factor in this study was that no attempt was made to quantify the individual growth factors. This kit will facilitate the design of randomized control trials to validate the indications for platelet use in a variety of musculo skeletal conditions.

## Conclusion

This technique of PRP preparation consistently gives the optimal platelet concentration. It can be used as a core technique for the design of RCT's to evaluate the rationale for using platelets in musculo skeletal conditions. Aseptic technique is assured as this is a closed method of extraction.



# Platelet-rich plasma therapy in tendinopathies

Dr Vijay Shetty, Dr Saurabh Talekar & Dr Aditya Kaja

## Introduction

Platelet-rich plasma (PRP) is an emerging, attractive and promising therapy for a number of musculoskeletal disorders. Although the efficacy of its use in orthopaedic clinical practice has been highly debated, the safety of its use has been well-evidenced. The use of PRP in tendinopathies has been gaining popularity among the orthopaedic and sports medicine specialists. Of late, there has been increasing use of PRP particularly in common tendon disorders such as tennis elbow, plantar fasciitis and Achilles tendinopathy. It is known that in the general population, the lifetime cumulative incidence of Achilles tendinopathy is 5.9 % among sedentary people and a staggering 50 % among elite endurance athletes and it is also estimated that plantar fasciitis has an incidence of 4 to 22 % among the population of runners. Patients

suffering from these tendinopathies often require lengthy rehabilitation or even surgical intervention, ultimately retiring from athletic activities. For these reasons, the use of PRP in tendon disorders has gained popularity in recent times. This article aims to look at the currently available evidence on the safety and efficacy of the use of PRP in orthopaedic clinical practice.

## The basic mechanism of action

Platelets are normal components of the blood. During a typical normal wound healing, platelets migrate to the area along with other cells (leukocytes). The platelets are activated, and they degranulate to release what are called growth factors. These growth factors play a role in stabilising the wound and begin the healing process. Platelet-derived growth factor (PDGF), peaking shortly after tissue damage, plays a central role in the healing process.

**The solution in question**

PRP is the plasma fraction of blood with a platelet count roughly 4 to 5 times above the baseline. There are various methods of PRP preparation and this day-and-age, there are many ready-to-use kits available commercially. When it comes to the treatment of tendinopathy, there is still much debate, on an ideal PRP preparation. There is debate about the type of preparation, debate about whether fresh or frozen PRP preferred, and there is debate about leucocyte-rich (LR-PRP) or leucocyte-poor PRP (LP-PRP). Researchers from France studied five different types of PRP preparations from a single donor and noticed significant variations in the prepared solution and postulated that this may be the reason for the variability of results in PRP studies. Again, there is enormous confusion about fresh PRP versus freeze thawed PRP.

Simply put, the current PRP preparations are either LR-PRP or LP-PRP. Our current thinking is LR-PRP is pro-inflammatory, and LP-PRP is anti-inflammatory.

**The evidence**

The use of PRP in the treatment of tendinopathies has been a subject of enormous debate. Table 1 shows some of the studies that have shown variable results with the use of PRP in different tendon indications.

Currently, high-quality evidence is available to support the use of LR-PRP for tennis elbow, moderate high-quality evidence is available to support the use of LR-PRP in patellar tendinopathy. PRP injection has also proven to be superior to corticosteroid injections in recalcitrant plantar fasciitis. However, there is not enough evidence even at this point to prove whether PRP therapy is an effective method of treatment for Achilles tendinopathy.

Study design characteristics for PRP versus control injection for tendinopathies

Indication	Study	Year of publication	Level of evidence	Sample size			Intervention/injection volume and contents			Follow-up (months)	Favors PRP?
				PRP	Control	Type of injections	PRP	Control			
Achilles tendinopathy	Boesen et al. [12•]	2017	I	20	20	LP- PRP	4 mL PRP + eccentric training	Sham injection + eccentric training	6	+	
Achilles tendinopathy	Krogh et al. [13]	2016	I	12	12	LR- PRP	10–15 mL lidocaine → 6 mL PRP	10–15 mL lidocaine → 6 mL normal saline	3	–	
Lateral epicondylitis	Behera et al. [14]	2015	I	15	10	LP- PRP	3 mL PRP + 0.5 mL calcium chloride	3 mL bupivacaine + 0.5 mL normal saline	12	+	
Lateral epicondylitis	Gautam et al. [15]	2015	I	15	15	LP- PRP	2 mL PRP	2 mL methylprednisolone	6	+	
Lateral epicondylitis	Lebiedzinski et al. [16]	2015	I	64	56	LP- PRP	3 mL PRP	1 mL betamethasone + 2 mL lidocaine	12	+	
Lateral epicondylitis	Mishra et al. [17•]	2013	II	112	113	LR- PRP	Bupivacaine → 2–3 mL PRP	Bupivacaine → 2–3 mL bupivacaine	6	+	
Lateral epicondylitis	Montalvan et al. [18]	2016	I	25	25	LP- PRP	2 mL lidocaine → 2 mL PRP	2 mL lidocaine → 2 mL normal saline	12	–	
Lateral epicondylitis	Palacio et al. [19]	2016	I	20	20	LP- PRP	3 mL PRP	3 mL dexamethasone	6	–	

NR not reported, LP-PRP leukocyte-poor PRP, LR-PRP leukocyte-rich PRP, → denotes sequential injection

**The conclusion**

It appears, from the available literature, that PRP is a safe alternative compared to other therapies in musculoskeletal tendon disorders. However, there is mixed evidence on the efficacy of this procedure on specific tendon problems (indications). There is a need for research comparing various types of PRP and Autologous blood injections and its efficacy in specific indications. Based on the currently available literature, LR-PRP appears to be an attractive option for tennis elbow, plantar fasciitis and patellar tendinopathies. Efficacy of PRP on Achilles tendon and rotator cuff is poor. Given that the use of PRP is safe, it is recommended that clinicians should take fully informed consent and discuss the pros and cons of this therapy and then offer this treatment to informed patients.

## PRP in OA Knee : Consensus Document

Dr. Koduru Satya Kumar

Osteoarthritis (OA) of the knee is one of the main causes of musculoskeletal disability. Autologous platelet-rich plasma (PRP), which contains a pool of growth factors, appears to offer an easy solution for delivering multiple growth factors needed for tissue repair. Today, PRP is being portrayed as a “wonder drug,” without sufficient evidence to support its application. Most reports of PRP use are anecdotal and stem from insufficient evidence. The procedure is under a cloud of skepticism as it is not approved by FDA for use in osteoarthritis of the knee. Before totally disregarding PRP one must keep in mind that powerful industrial influences may be at play as this modality has the potential to reduce the number of interventions ( TKRs ) which might adversely affect their balance sheets. We have reviewed three studies of which two draw from personal experience and arrived at a broad guidelines for those interested in practicing PRP therapy.

### Study #1

**Treatment With Platelet-Rich Plasma Is More Effective Than Placebo for Knee Osteoarthritis : A Prospective, Double - Blind, Randomized Trial Sandeep Patel,\* MS, Mandeep S. Dhillon,\*y MS, FAMS, Sameer Aggarwal,\* Neelam Marwaha,z MD, FAMS, and Ashish Jain, MD "The American Journal of Sports Medicine, Vol.41, No.2, 2013."**

Sandeep Patel et al in their study support the short-term effectiveness of PRP injection over a placebo for relieving pain and stiffness and improving knee functions in early knee OA. Benefits in early OA are more pronounced and a single dose of PRP is as effective as a double dose. The effect tends to taper off over time, leaving open the option of staged injections over many months as a potential future therapeutic regimen.

### Study #2

**Role of double vs triple shot intra articular platelet rich plasma in early osteoarthrosis of knee  
Dr. K Satya Kumar, Dr.Riyaz Babu**

**Shaik, Dr.Lakshmi Narayana Paladugu and Dr.Amarnath Surath**  
**International Journal of Orthopaedics Sciences 2018; 4(2): 48-50**

This is a prospective study in which 120 patients were involved. All 120 were of Kellegren Lawrence grade-II. Forty five of them were male and 75 of them were female. A total of 135 knees were involved, half the patients were given two shots of intra articular injection of PRP along with post procedural oral analgesics for 1 week and the other half were given three shots of intra articular injection of PRP, with topical analgesia without oral analgesics. Results were analysed using pre and post procedure VAS pain scale grading and patient questionnaire.

### **Conclusion**

As already known platelet rich plasma induces tissue healing and has good regenerative capacity which is the main basis for its usage in osteoarthritis. I conclude in my study that for KL-GRADE2 (A1&B1), early osteoarthrosis of knee two shots of intra articular injection of platelet rich plasma with minimal use of analgesics is enough to show short term good results. Very few patients needed a

third injection of PRP. For KL-GRADE2 (A2 & B2) early osteoarthrosis of knee three shots of intra articular PRP injection, with topical analgesia without oral analgesics showed excellent long term results. This study helped us in selecting the number of PRP injections to be used in KL grade 2 OA. Patients who received 3 shots of PRP showed excellent long term results without use of oral analgesics. Its efficacy in more than 2 years follow up to be studied further.

### **Study #3**

**Dr Amarnath Surath and  
 Dr Pavan Kumar**

Telephonic interview of patients who received PRP injections for KL Grade-I & II OA knee between 2016-18. The protocol was to give three injections at two week intervals. The volume of PRP taken was 3ml which gave platelet counts in the range of 10-18 lacs. Injection was given with the knee flexed 90 degrees to one side of the patellar ligament. Patient was advised quadriceps exercises as tolerated. A total of 106 patients were contacted over telephone and answered a questionnaire regarding response to PRP therapy. Twenty seven of them could not be contacted

and were lost to follow up. Sixty patients were between ages 35-55 years and 18 more than 55. Male female ratio was predominantly female ( M19 : F 41 ).

Results : Twelve patients who had a single injection and dropped out of the study. Among the remaining patients VAS improved around 50% in 40 patients and 50-75% improvement

in eight patients. All 48 patients were not on NSAIDs and able to do their ADL. Patients aged above 55 years had a different story to tell. Six patients had no relief at all, and 12 had improved VAS scores. In all patients there was reduction in pain but they needed NSAIDs occasionally. There was no significant improvement in walking distance or stair climbing.

### **The Consensus**

- ▶ **KL Grade I & II are ideal for PRP injection.**
- ▶ **Varus & Valgus deformity should be ruled out with Scanogram.**
- ▶ **Optimal injection sequence is 3ml x 3 times at 2week intervals.**
- ▶ **PRP injection must be followed by Knee ROM and Quads exercises.**



## Bone Marrow Aspirate Concentrate (BMAc)

Dr. A.V. Dakshina Murthy

In adult skeleton there are two types of bone marrow which are red marrow and yellow marrow. Yellow marrow is filled with adipose tissue and is inactive by function. Red marrow possesses hematopoietic cells and mesenchymal stem cells. Mesenchymal stem cells (MSC) have the capability to differentiate into cell lines like cartilage, bone, tendon, muscle and nerves. Benefits of BMAc are achieved either by proliferation and differentiation into variety of cell lineages or by elution of growth factors and cytokines to hasten the process of healing in tissues with attenuated healing potential.

### Components of BMA

In normal bone marrow aspirate (BMA), common components present are erythrocytes (22-28%), neutrophils (32-37%), lymphocytes (13%), eosinophils (2.2%), blast cells (1.4%), monocytes (1.3%), basophils (0.1%) and megakaryocytes in variable

percentages. Apart from the above components, BMA contains mesenchymal stem cells and various growth factors. An adult bone marrow has about 0.001% to 0.01% of mesenchymal stem cells in 7-30 cells per million nucleated cells. Growth factors like PDGF, TGF- $\alpha$ , BMP2 and 7 and IL-1RA are also present in the BMA in variable concentrations (Table-1).

Main aim of bone marrow concentration is to increase the cell count of mesenchymal stem cells. The concentrations of MSC in bone marrow alone is relatively low, hence the aspirate is concentrated by centrifugation in order to increase the percentage of MSCs. Cell count in bone marrow aspirate is  $612 \pm 134$  per  $\text{cm}^3$  compared to bone marrow aspirate concentrate is  $2579 \pm 1121$  per  $\text{cm}^3$  which is a fivefold increase in the number of mono nuclear cells (Figure 1).

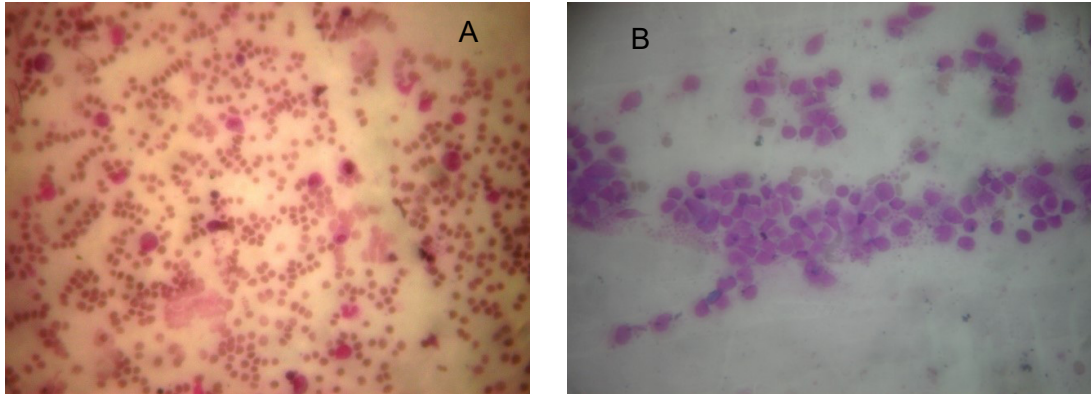


Figure 1 : Histopathological picture showing mesenchymal stem cells in bone marrow aspirate with admixture of RBC. (A), mesenchymal stem cells in BMAC extracted by density gradient centrifugation (B).

**Table-1: Growth factors present in mesenchymal stem cells**

GROWTH FACTORS	FUNCTIONS
PDGF	Stimulates cell proliferation Chemotaxis Stimulates angiogenesis
TGF- $\beta$	Stimulates production of collagen type I and type III Angiogenesis Re-epithelialization Prevents collagen break down
BMP2	TGF- $\beta$ signaling pathway Hedge hog pathway Cytokine and cytokine receptor interactions
BMP7	Phosphorylation of SMAD1 and SMAD5- induce transcription of numerous osteogenic genes.
IL-1RA	Pain relief

### Bone marrow Aspiration

Commonest source of bone marrow aspiration is from iliac crest, tibia or calcaneum. Among all of the sources, iliac crest yields highest concentration of mesenchymal stem cells. Graft is harvested by sector rule in iliac crest, which roughly divides the entire iliac crest into six zones. Of these six zones the posterior crest is preferred site as it contains higher concentration of MSCs (higher by 1.6 times compared to anterior iliac crest).

Concentrating the bone marrow will eliminate non-nucleated cells like red blood cells and increase in the number of mesenchymal cells.

### Protocol for BMAc FICOLL density gradient centrifugation

- ▶ Aspirate bone marrow into heparinized 10ml syringe.

- ▶ After aspirating 1.5 to 2ml of marrow the needle must be withdrawn by a few millimeters and rotated 90 degrees to reduce the admixture of peripheral blood. The number of aspirations per site should not exceed 6-8, after which the needle placement in bone should be changed. (Figure 2)

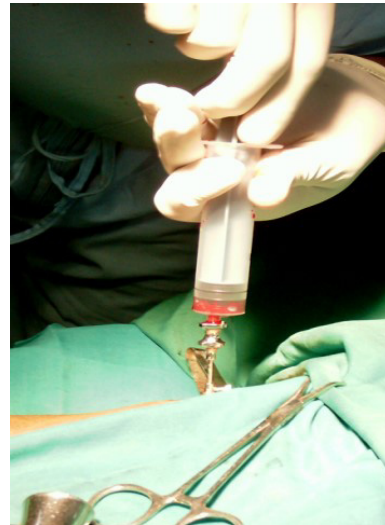

Figure 2 : Aspiration of Bone marrow from anterior iliac crest.

- ▶ Collect into 50 ml centrifugation tube with 8ml heparin.
- ▶ Take 25 ml Ficoll in four 50ml conical bottom centrifugation tubes.
- ▶ Layer 25 ml of marrow on top with tube tipped at 45 degrees. (Figure 3)

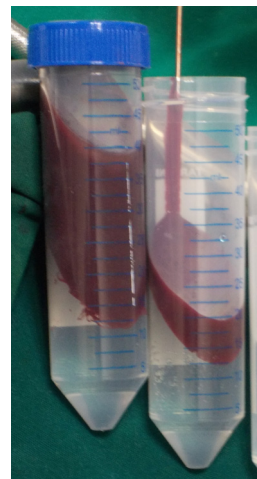


Figure 3 : Layering of bone marrow aspirate over ficoll solution.

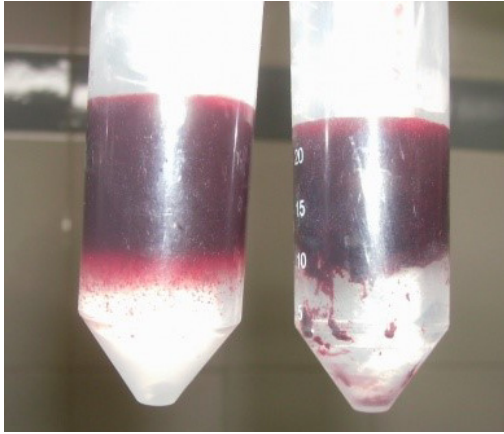



Figure 4: Tubes before centrifugation.

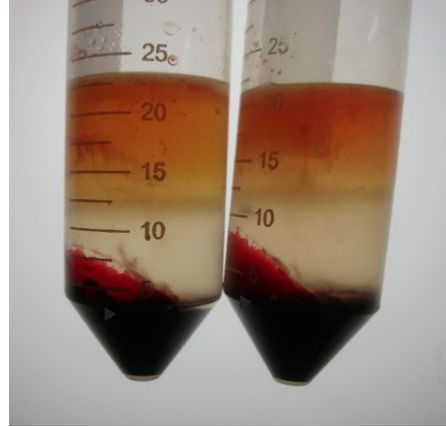

Figure 5 :Concentrate obtained after centrifugation.

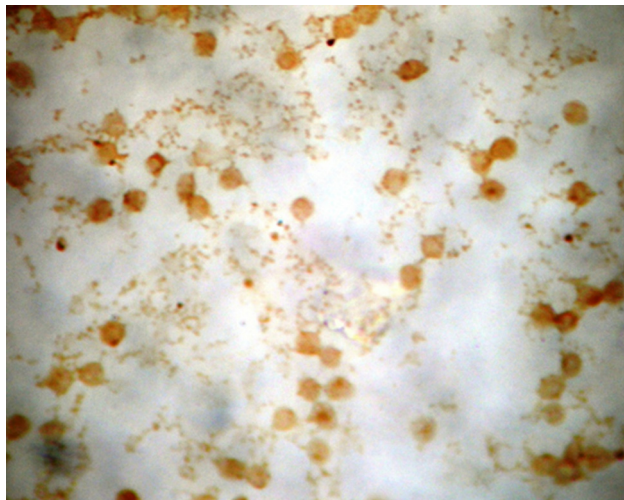
- ▶ Centrifuge at 2500 rpm for 40 minutes.
- ▶ Aspirate the smoky layer (arrows) at the interface between plasma and ficoll. (Figure 5)
- ▶ Add 3 volumes of Phosphate buffered saline to the cells, centrifuge@2000 rpm for 10 minutes.
- ▶ Repeat and wash again
- ▶ Resuspend and use. Approximate yield of BMAc from 100ml of marrow is 5-7ml. (Figure 6)

Figure 6: Mesenchymal cells pellet.



### Identification of Stem cells

The mere presence of mononuclear cells does not confirm the presence of mesenchymal stem cells. CD34 marker is used to identify stem cells. (fig.7)



The concentration of mononuclear cells was measured using an automated cell counter and increase in cells was documented (fig.8)

#### Marrow Counts

```

DATE:18/01/2019
ID : HUSSAIN
SEQ.# : 8
STARTUP PASSED
T: 28.5 Deg C

WBC : 20.0 H 103/mm3
RBC : 6.01 H 106/mm3
HGB : 14.1 g/dl
HCT : 45.9 %
PLT : 250 103/mm3
PCT : .171 %

WBC Flags : G1
DIFF :
%LYM: 21.7 %
%MON: 5.7 %
%GRA: 72.6 %
  
```

#### BMAc Counts

```

DATE:18/01/2019
ID : HUSSAIN
SEQ.# : 10
STARTUP PASSED
T: 28.3 Deg C

WBC : 58.9 H 103/mm3
RBC : 0.16 L 106/mm3
HGB : 0.0 L g/dl
HCT : 1.3 L %
PLT : 1091 H 103/mm3
PCT : .824 H %

WBC Flags : M2 G1 G2
DIFF :
%LYM: 52.4 H %
%MON: 18.4 H %
%GRA: 29.2 L %
  
```

### Complications

In literature very few complications during harvesting and administration are described with low incidents in table 2

**Table: 2 complications during procedure**

During harvesting	During administration
Hemorrhage	infection
Neurovascular injury	Pulmonary embolism and respiratory complications
Pathological fracture	tumor genesis

#### Clinical applications :

- ▶ Non union
- ▶ Bone defects

Hernigou et al. used Bone Marrow Aspirate Concentrate in the treatment of atrophic non-union in 60 patients. A positive association between the quantity of hard callus and the number ( $p = 0.04$ ) and concentration ( $p = 0.01$ ) of fibroblast colony forming (FCF) units in the graft was reported by them. In the seven non-united tibias, the concentration ( $p = 0.001$ ) and the total number ( $p < 0.01$ ) of progenitors cells injected were significantly lower than in those that have united. One more finding they made was in the time interval needed to achieve union. This

was negatively correlated with the FCF units' concentration at the site of the graft ( $p = 0.04$ ).

- ▶ Avascular necrosis

Studies were conducted on management AVN of the femoral head AVN using BMAC injection

Of all Hernigou and Beaujean were the first to describe the protocol for this . They combined BMAC injection with conventional core decompression (CD). BMAC was inserted into the necrotic area within the femoral head.

189 hips were studied with this procedure.

Their results were....excellent outcomes in 93% hips at the pre-

collapse stage, with only six percent cases required total hip replacement (THR) later

- ▶ Arthrodesis
- ▶ Benign bone lesions
- ▶ Chondral defects

Giannini et al tried the use of BMAC as a single-step technique for the reconstruction of cartilage defects of the talus, comparing this procedure to open or arthroscopic autologous chondrocyte implantation (ACI)

In the above study of 81 patients the mean American Orthopaedic Foot and Ankle Society (AOFAS) score improved significantly ( $p < 0.0005$ ) at an average of  $59.5 \pm 26.5$  months. There were no significant differences in the change of AOFAS scores between the all groups. Histological evaluations emphasised the formation of type II collagen and proteoglycan expression. However, BMAC provided the advantage of permitting a noticeable decrease in morbidity as a “one-step” technique

- ▶ Spinal fusion
- ▶ Osteoarthritis - In osteoarthritis, as per literature BMAC is more effective in Kellgren-Lawerance grade 2

changes than grade 4 changes. Two to six injections at an interval of two to three months is advised for excellent results. Main complications are pain and swelling for six to eight weeks. Hence BMAC can be recommended for early stage of osteoarthritis.

#### ▶ Tendon injury

A prospective multicentre study was done by Centeno et al This study compared the results of use of BMAC for the treatment of osteoarthritis (OA) shoulder having rotator cuff pathology and the use of BMAC for the treatment of osteoarthritis without any rotator cuff pathology.

A total of 115 shoulders were treated with BMAC injection principally for glenohumeral OA . The study includes both categories of cases, i.e glen humeral OA with rotator cuff tears and without a rotator cuff tears

The mean disabilities of the arm, shoulder and hand score and VAS improved significantly from 36.1 to 17.1 ( $p < 0.001$ ) and 4.3 to 2.4 ( $p < 0.001$ ), respectively. These results were consistent with a mean subjective improvement of 48.8%. They reported

no significant adverse events at two years follow-up post surgery

- ▶ Low risk of infection
- ▶ Day care procedure

### Disadvantages

### Advantages of BMAC are

- ▶ On site procedure
- ▶ No amplification or manipulation of cells
- ▶ No risk of disease transmission

- ▶ Pain due to local anesthesia
- ▶ Variable quantity of cells
- ▶ Side effect of erythrocytes

### Keypoints :

- ▶ BMAC is a rich source of haematopoietic stem cells.
- ▶ Ficoll separation is “gold standard”.
- ▶ Performed in operation theatre with low logistical requirement & cost.
- ▶ Will hasten the process of healing in tissues with attenuated healing potential.

## BMAc in Nonunion of Fractures

Dr. Amarnath Surath

Bone union is the desired endpoint after any fracture. Many factors influence fracture healing in the form of patient selection, implants and surgical technique. Three components are needed for fracture to progress to healing, namely the presence of stem cells, growth factors, and a biologic scaffold are integral to this process. Bone marrow aspirate (BMA) has been utilized as a source of bone marrow-derived mesenchymal stem cells (BM- MSC) with its relative ease of harvest, low morbidity, and feasible cost. Bone marrow contains low percentage of mesenchymal stem cells (MSCs), .001-.01% of nucleated cells. Typically the aspirate is concentrated by centrifugation to increase the ratio of MSCs. Concentrated bone marrow aspirate (CBMA) provides both stem cells and growth factors and relies on the host tissue to provide scaffold. BMAc has proved itself as a valuable adjunct in treatment of fractures, cartilaginous defects and tendon injuries. This chapter will confine itself to its role in fracture healing. Evidence

suggests that stem cells act to direct local cells to stimulate regeneration and repair that is specific to each tissue. This process is mediated by secretomes from the stem

cells, which allow their adaptation in each environment and therefore provides the appropriate growth factors and cytokines necessary to stimulate each tissue in a different fashion.

Bone consolidation and time to bone union was improved in patients receiving BMAc, with faster healing rates when compared to patients in the autograft group. One study found a significantly lower number of progenitor cells in patients who did not achieve union. Time needed to obtain union correlated directly to the concentration of colony forming units in the graft. Lastly, one study evaluated the efficacy of BMAc in the treatment of open tibia fractures and found adequate bone consolidation and bone callus formation in all patients. BMAc application was used in combination with Demineralised Bone Matrix/

rhBMP-2, freeze-dried allograft, or cancellous bone chips. Present experience is with direct injection into freshened fracture site with or without addition of fibrin sealant (Tiseel). Injection of BMAC into the site of nonunion was accomplished by fluoroscopic visualization.

BMAC isolation was by density gradient centrifugation with Ficoll as described in the previous chapter. The residual ficoll was removed by serial washes (two) and 0.3 ml of the sample was sent for vital staining (Trypan Blue stain), IHC with CD-34 which will stain MSC's and cell count. Once yield and vitality were established the sample can be injected into fracture site. The addition of fibrin sealant is the choice of the surgeon but it adds to the cost of the procedure.

#### **Inclusion Criteria for BMAC injection for Delayed/Non Union**

A diagnosis of nonunion was made by the clinical examination and radiographic data. Clinical evidence of a nonunion was determined by documented pain and motion at the fracture site. "Nonunion" was determined by a lack of radiographic

evidence of bone bridging on 3 of 4 cortices in two planes of X-rays at 6 months after injury or a fracture that had not shown in any progression of healing over a three-month period.

#### **Exclusion criteria**

Exclusion criteria were presence of infection clinically or by positive inflammatory markers, ongoing treatment with immunosuppressant drugs including glucocorticoids, chemotherapy or colchicines. Patients were excluded if they were pregnant or during lactation. Patients with autoimmune deficiency syndrome, hepatitis, or a medical history of alcohol or drug abuse were also excluded.

#### **Assessment of bone healing**

All patients were monitored using the same protocol during the postoperative period. Patients were followed up in the outpatient clinic for 1 month, 3 months, 6 months, 9 months, 12 months, 18 months, and 24 months after the procedure. The physical examination assessed pain, sensation of stability, and

ability to walk with or without crutches. X-rays were taken in two

standard planes (anteroposterior and lateral) at all visits. Radiographic evaluation was performed via X-ray analysis. Assessment of new bone formation and remodelling was based on the modified Lane and Sandhu radiological scoring system. The score for bone formation was defined as 0 (no new bone formation), 1 (<25% new bone formation), 2 (25–50% new bone formation), 3 (50–75% new bone formation), or 4 (>75% new bone formation). The score of union was 0 (full fracture line), 2 (partial fracture line), and 4 (absent fracture line). The remodeling score was 0 (no evidence of remodeling), 2 (remodeling of the intramedullary channel), and 4 (full remodeling of the cortex). The maximum points could be achieved was 12. Fracture healing was assessed by lack of pain during

weight-bearing and bridging of three out of four cortices in both anteroposterior and lateral radiographic views (Liebergall et al., 2013). Bone union was established when both clinical and radiographic evidence

were in agreement (Tressler et al., 2011). Evaluation of the radiographs

as part of the clinical follow-up was performed by the non-blinded surgeons. Every side effects resulting from the procedure were assessed and recorded. Partial weight bearing was only allowed after the appearance of the bone callus and with signs of stability upon physical examination. The defined clinical protocol established that, if the patient did not present signs of bone consolidation six months after the procedure, a second intervention would be indicated, a situation considered a treatment failure.

### Procedure

Once diagnosed with non/delayed union based on clinical and radiological findings the patient was taken up for BMAc injection. First and foremost the patient and relatives were counseled that the procedure may not produce the desired result i.e. bone union and the possibility of requiring multiple injections was explained. Under aseptic conditions, in the operating theatre, bone marrow was aspirated and processed as mentioned in the previous chapter. The average yield of BMAc from 100ml of bone marrow is

5-10ml. The patient is suitably anaesthetized, draped and fracture site identified under fluoroscopic guidance. A small stab incision was given and fracture site was freshened with

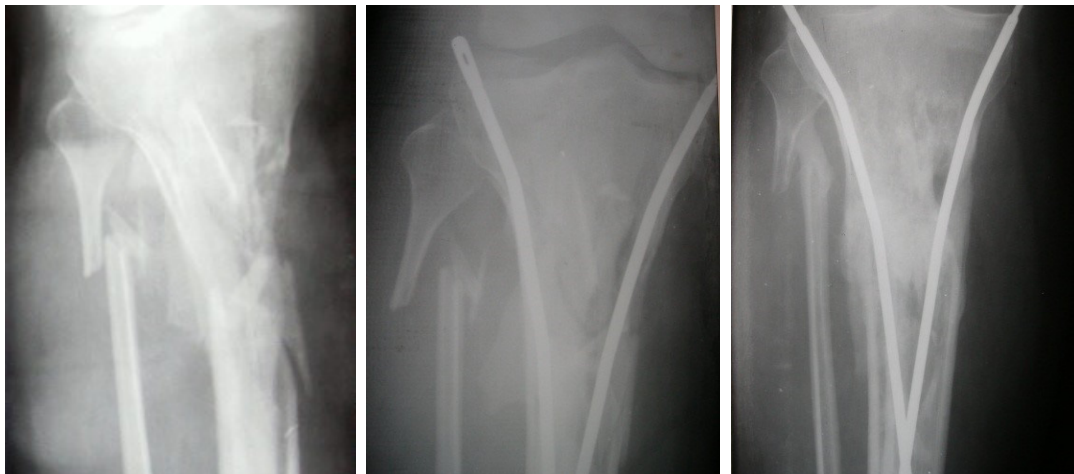curettes. The BMAC was then injected into fracture site through a different track. Serial radiographs were taken for follow up.

### Case Studies

#### # Case 1

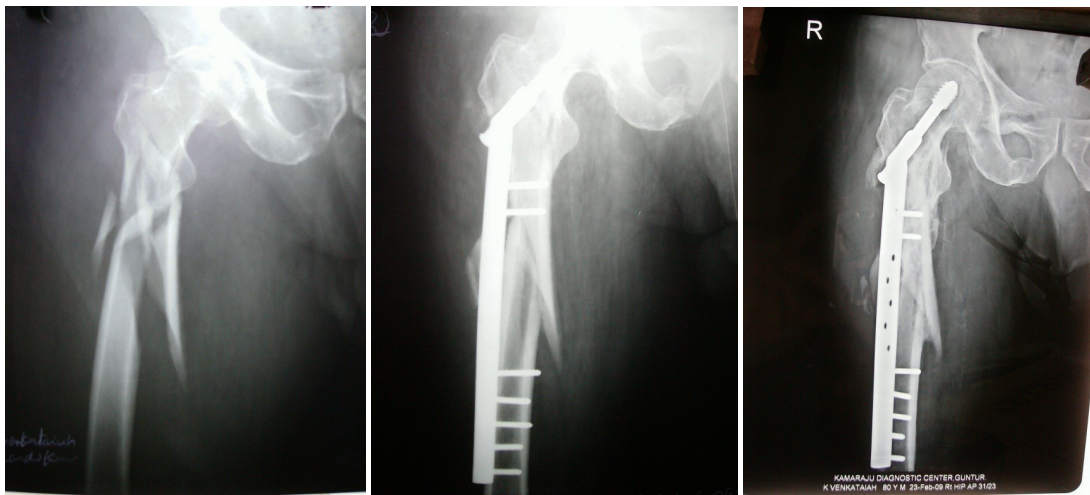Male, 23 yrs presented with left proximal tibial fracture following RTA. Xrays showed grossly comminuted proximal tibia fracture ( Fig 1a ) with swelling of the soft tissues and blisters. Fracture was stabilized with Ender nails and POP slab ( Fig 1b ).

Three weeks following fixation BMAC injection was carried out into the fracture site under fluoroscopic guidance. No attempt was made to freshen the fracture site as it would disturb the scaffold formed in the interval between the fracture fragments. Complete consolidation was observed at 20 weeks (Fig 1c).

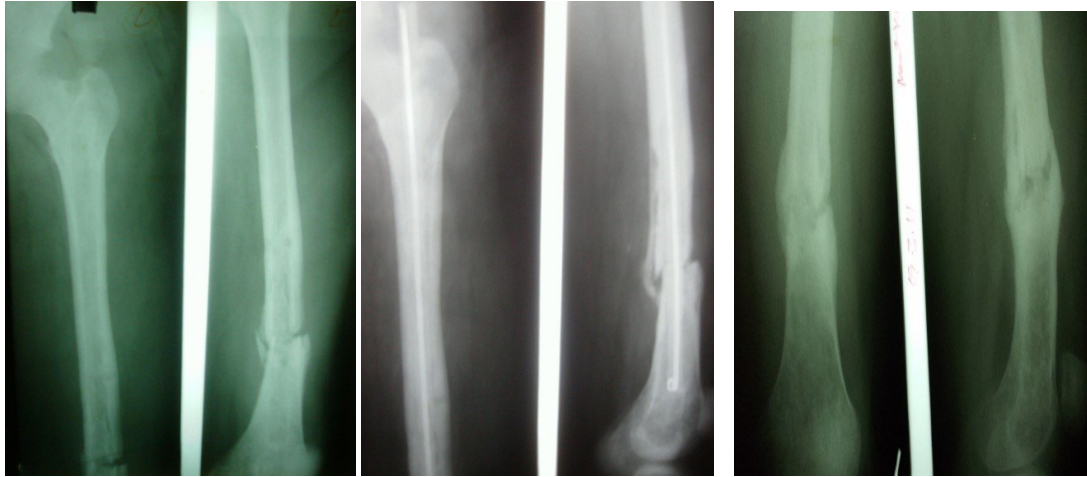

**# Case 2**

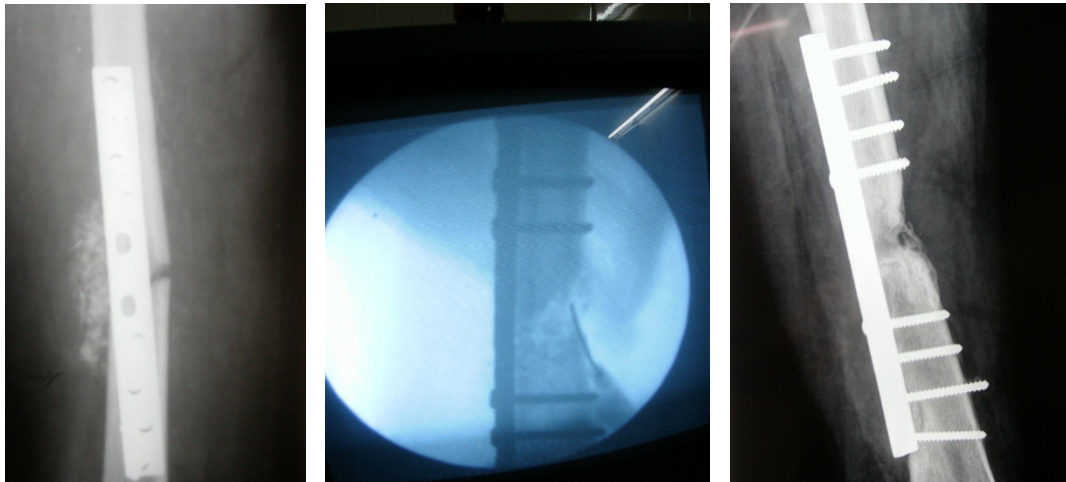
Male, 80 sustained comminuted sub trochanteric fracture of the right femur due to fall from stairs ( Fig 2a ). DHS fixation was carried out but due to extensive comminution biological fixation was achieved ( Fig 2b ). At six weeks BMAc was injected in between the fragments and the fracture consolidated in twenty weeks. The follow up Xray at 6 months shows stable bone healing and patient was ambulatory without support (Fig 2c).

**# Case 3**

Male, 21 sustained pathological fracture of the left distal femur secondary to chronic osteomyelitis (Fig 3a). Antibiotic PMMA coated nail was inserted to stabilise the fracture. Infection was controlled but fracture showed evidence of delayed union (Fig 3b ). He received two injections of BMAc at 8wks and 12wks. The fracture consolidated by 24 weeks and resulted in bone union as well as infection control (Fig 3c).

**# Case 4**

34 year old male sustained open fracture mid shaft femur in RTA. He underwent ORIF and primary bone grafting after thorough debridement and lavage. BMAC was injected into the bone graft at six weeks and fracture consolidated by 20 weeks ( Fig 4 ).



**Conclusion**

BMAC consistently results in fracture healing and has a definite role as an adjuvant. It precludes the need for cancellous bone grafting with the resultant morbidity of an additional surgical intervention. It can be performed as a day care procedure.



## **Mesenchymal Stem Cells in Management of Avascular Necrosis Femur Head**

**Dr. Ramesh K Sen**

Osteonecrosis (Avascular necrosis) of the femoral head (ONFH) is a disorder with a spectrum of different etiologies. Exact pathogenesis is still not clear. The clinical presentation is variable with some patients having significant symptoms in early phase of the disease while in others, it may not manifest clinically till femur head is collapsed. Among many etiological factors, steroids and alcohol remain the common causes, but in many patients, no clear reason can be defined. While x rays may not help in the initial stage of lesion, MRI is usually the diagnostic investigation. As it runs a slow course in most patients, a conservative approach of non-weight bearing has been advocated. There have been a lot of interest in medical management especially bisphosphonates, but still universal acceptance is lacking. Most orthopedic surgeons carry the perceptions that total hip arthroplasty is the final and an essential procedure in most patients.

At an early stage of presentation, common surgical intervention has been the core decompression, with the goal of delaying or preventing the need for THA. Even though this procedure has been used for many years, its efficacy has remained controversial with no consensus in literature. One of the reasons proposed for its failure was lack of induction of any osteogenic activity in the necrotic area. The development of regenerative medicine has now gone beyond this limit and in recent years core decompression has been supplemented with additional procedures like an osteoinductive agents that can enhance bone repair.

Stem cells are a group of cells with the ability to self-renew and form differentiated cells. These cells play important roles in development and disease. Adult stem cells, which include mesenchymal stem cells (MSCs), have been reported as a promising approach for the regeneration of various tissues. MSCs

were first described in human bone marrow and called bone marrow stem cells (BMSCs). These cells however can be isolated from many other sources also, including adipose tissue, the synovial membrane and the umbilical cord etc.

Hernigou et al were the first to report in 2002, that these mesenchymal Stem Cells can improve surgical outcomes of CD technique in avascular necrosis femur head. They hypothesized that there is an insufficient supply of progenitor cells enhancing bone remodeling in areas of AVN in patients with ONFH. The MSCs are instilled into the necrotic area after core decompression. They also proposed that these nonhematopoietic progenitor cells differentiate in osteoblasts under the influence of growth factors such as bone morphogenetic proteins, platelet-derived growth factor (PDGF), transforming growth factor  $\beta$  (TGF- $\beta$ ), insulin like growth factor, fibroblast growth factor (FGF), and parathyroid hormone. Thus combination of MSCs transplantation and CD surgery can enhance femoral head repair promoting reconstruction and

creeping substitution of new bone. Hernigou et al. publishes a clinical study using core decompression and autologous bone marrow transplantation for the treatment of 189 hips in 116 ONFH cases. Only 9 cases of 145 hips, operated during Ficat stages I-II, required hip replacement after a mean 7-year follow-up, whereas 25 of 44 hips treated during Ficat stages III-IV, needed joint arthroplasty. Subsequently Gangji et al in a prospective, randomized, double blind trial, compared the surgical outcome of 2 groups of patients treated with isolated CD or CD and implantation of autologous bone marrow cells. In 24 cases at ARCO Stage I and II, they observed a significant improvement of pain and lower rate of radiographic progression in the group treated with the combined approach. However, they did not report a significant difference in both the groups in terms of subsequent THA.

Many clinical studies have now appeared in literature where the therapeutic effect of stem cells on ONFH have been evaluated. Majority of authors demonstrated positive clinic outcomes, including reduced pain,

improved function and motion, delayed progression or the avoidance of THA. However, few others like Pepke et al. did not report any significant benefit from the additional injection of concentrated bone marrow aspirate compared with the effects of CD alone in the short term. Some retrospective comparative studies also drew similar conclusions.

A recent meta-analysis however showed the usefulness of implantation of autologous MSCs into the CD track, particularly in the early (precollapse) stages of ONFH, and concluded that combined use of CD with MSC instillation could improve the survivorship of femur heads and reduce the need for hip arthroplasty. Another meta-analysis having eight randomized controlled trials also demonstrated the benefit of the combination of CD with regenerative techniques as compared with CD alone, in providing a significant improvement in survivorship over the time.

There can be controversies due to heterogeneity among studies, including differences in patient

selection, cell harvesting, cell processing, and cell delivery etc. but overall, it seems that the general outcomes of the use of stem cells to treat ONFH have been good.

Some studies have looked into the factors which may affect the outcome of treatment in using MSC in AVN. Most understood factor in usage of stem cell therapy is the stage of ONFH as reported by Ma et al. Hauzeur et al. also looked into the delayed cases and reported that in stage III ONFH, the implantation of bone marrow aspirate concentrate (BMAC) after CD did not produce any improvement. The stage III and stage IV patients may not be the candidates for this therapy while early-stage (stage I or II) patients will be a more appropriate choice. In addition, authors have observed reported that patients with posttraumatic osteonecrotic hips had different outcomes than did patients with non-traumatic hips, suggesting that etiology also affects clinical outcomes. It has also been very well documented that patients with a low modified Kerboul grade achieve better results. It seems that the stage, size, morphology and even etiology of

ONFH may be important factors associated with the treatment outcome. Thus, patient selection is critical in treatment outcome in usage of stem cell therapy in ONFH.

It has also been seen that aging is a factor in decreased number of MSCs isolated from a donor and the proliferation ability of those cells. Stenderup et al. have also reported that although MSC function was decreased in cells isolated from older donors *in vitro*, this difference might not affect the ability of the cells to differentiate *in vivo*. The authors concluded that MSCs isolated from older donors maintained normal cellular function but showed a proliferative defect. While Aksu et al. observed that sex may affect the differentiation potential of human adipose-derived stem cells, Sen et al. did not observe sex differences, side of involvement, and opposite side involvement, having any effect on the outcomes.

Various types of MSCs have been used to treat ONFH, including bone marrow-derived MSCs, adipose-derived MSCs and peripheral blood MSCs. Among these BMMSCs are

the most commonly used type. Mostly used as bone marrow concentrate (BMC) or after culture to augment the cell population. Rastogi et al. compared isolated mononuclear cells with unprocessed bone marrow instillations and observed the improvements in hip function, as measured by the Harris hip score, in both groups. There was a decrease in the lesion size in the processed isolated mononuclear cell group, and 3 of 30 hips in the unprocessed bone marrow injection group required total hip replacement. It seems that the more effective procedure had better outcomes than did unprocessed bone marrow injection for the treatment of ONFH.

Adipose tissue derived stem cells are less expensive but also less invasive and painful than that used for bone marrow harvesting. An *in vitro* study demonstrated that adipose-derived MSCs may provide a more robust growth rate and bone differentiation potential than bone marrow-derived MSCs. Although the results of these studies seem encouraging, there is a lack of well-designed clinical studies to confirm this opinion. It has been well documented

that the osteogenesis and proliferation of MSCs are decreased in alcohol-induced and steroid-induced ONFH patients. Therefore, the efficacy of stem cells isolated from these patients may not have similar therapeutic effects. Allogeneic stem cells derived from healthy humans may be an option in treating ONFH in such individuals. There is evidence of low-immunogenicity MSCs, allowing the MSCs to be transplanted between HLA-incompatible individuals. Human umbilical cord mesenchymal stem cells (hUCMSCs) collection is easy, ethically feasible, yield of UCMSCs is high, and the cells have low immunogenicity. UCMSCs are also easy to separate and can be amplified in vitro; placental UCMSCs can typically be grown in culture for 30–40 generations, while adult BM MSCs can grow only 6–10 generations with the same performance. Cai et al. performed the co transplantation of autologous BM MSCs and allogeneic UCMSCs for treating ONFH and observed therapeutic effects without severe adverse effects at 12 months after transplantation. Chen et al. analyzed the clinical effects of transplanting

allogeneic hUCMSCs for the treatment of ONFH and observed clear results with no obvious side-effects after a 3-year follow-up. Studies with larger numbers of patients and longer follow-up times are needed to further evaluate the efficiency and safety of the use of allogeneic hUCMSCs in treating ONFH.

The prevalence of connective tissue progenitors in the bone marrow in the iliac crests of patients was about one per 30,000 nucleated cells. Hernigou et al. reported that according to the mean nucleated cell count per ml ( $18 \times 10^6$  cells), the bone marrow harvested from the iliac crest by aspiration contained an average of approximately 600 progenitors per ml [38]. If expansion is performed in vitro, more cells will be harvested. It is expected to have good outcomes with high nucleated cell counts [20, 23] but the optimum number of cells for injection remains unknown. Based on a mean bone matrix of 33% in cancellous bone, it has been estimated that there will be about 20 million osteoblasts or osteocytes per  $\text{cm}^3$  of new bone [39]. Thus, approximately  $3 \times 10^8$  (20 million cells/ $\text{cm}^3 \times 15 \text{ cm}^3$ )

osteoblasts or osteocytes are needed for new bone repair.

Achieving an objective number of osteoblasts or osteocytes depend on how many times the stem cells can proliferate and how many cells can effectively differentiate into osteoblasts or osteocytes, especially in the usually ischemic and anoxic micro environment of the necrotic area of the femoral head. On the other hand, whether the injection of more stem cells is better and whether there is a safe threshold for the maximum injection of stem cells remain unknown.

Based on current reported studies, except for patients injected with approximately  $24 \times 10^3$  to  $25 \times 10^3$  cells in early studies reported by Hernigou et al. the number of cells used in most other studies ranged from  $10^6$  to  $10^9$ , and the most frequently used number was  $10^8$  cells. Thus, based on current data, the injection of  $10^6$  to  $10^9$  cells may be reasonable. However, the optimal number still needs to be investigated.

Many techniques for cell delivery have been described , and such

techniques have been usually combined with CD. Other techniques include stem cells in impaction allogeneic bone grafting, auto-iliac cancellous bone grafts, porous tantalum rod implantation procedures, porous tantalum rod implantation combined with vascularized iliac grafting, interconnected porous calcium hydroxyapatite (IP-CHA) and porous nanohydroxylapatite.

There has also been attempts using the MSCs through arterial injection in management of AVNHF. Cai et al. transplanted MSCs into the medial circumflex femoral artery, the lateral circumflex femoral artery or the obturator artery through digital subtraction angiography and observed a therapeutic effect on avascular necrosis of the femoral head (ANFH) without severe adverse effects. Mao et al. also observed that intra-arterial infusion of PBMSCs could enhance the efficacy of biomechanical support during the treatment of ONFH. However, it is difficult to say that whether the topical application or intra-arterial infusion of MSCs is more effective.

Some studies also used local injection with platelet-rich plasma (PRP), pharmacological treatments, such as intravenous iloprost and oral bisphosphonates, or physical therapy, such as low-intensity pulsed ultrasound (LIPUS).

One of the major concerns in cell therapy is safety. Stem cells have some properties similar to cancer cells, i.e. a long lifespan, relative apoptosis resistance, and the ability to replicate for extended periods of time. The growth regulators and control mechanisms are similar in both cancer and stem cell maintenance. There remains a possibility, that stem cells may undergo malignant transformation. It has also been reported that the transplantation of embryonic stem cells

may increase the risk of teratoma formation. Other concerns, including immune rejection and genetic modification, also limit the clinical use of directly transplanted stem cells for ONFH.

After a review of current studies that used stem cells in the treatment of AVNFH, most studies reported no severe complications. There has been report of complications like flushing, mild headache and fever in some studies. Thus, based on the current studies, it seems that the application of stem cells for the treatment of ONFH is relatively safe.

To conclude it can be safely assumed that stem cell therapy in AVN of femur head is a viable option with literature largely in support of it.



# Orthobiologics in the treatment of Early Osteoarthritis - a Systematic Review

Dr. Karthik Pingle

## Introduction

Osteoarthritis (OA) of knee is one of the most common clinical presentation in these days among elderly especially. In Osteoarthritis, as there is ageing there is cartilage failure due to decreased inhibitor production and also reduced chondrogenic progenitor cells to repair the worn out cartilage tissue. Recent research continues to highlight the complex nature of OA, with confirmed or likely risk factors including demographic characteristics, obesity and dietary factors, joint loading and injury, and joint shape and alignment.

There are a number of non-operative options for the treatment of early OA. The routine choices include non-steroidal anti-inflammatory drugs (NSAIDs), muscle relaxants, physiotherapy, knee braces, life style modification, chondroprotective agents (diacerein, glucosamine, chondroitin sulphate), viscosupplementation i.e.

intra-articular hyaluronic acid (HA). The efficacy of Orthobiologic agents in the treatment of early OA has been reported in the literature recently.

Of late, Orthobiologics have evolved as one of the prominent treatment modalities for early osteoarthritis (OA) of the knee. Biological therapy also called as “cellular arthroplasty” is evolving as a new paradigm in the management of OA. Exploiting the healing and rejuvenating properties of body's own cells for the repair and renewal of damaged tissues is the basic crux behind Orthobiologic therapy. Repair of damaged cartilage and biological restitution can be possible by the judicious use of autologous biological products. In the treatment of OA, Orthobiologics occupy an intermediary position between the noninvasive conservative management at one end and the more invasive surgical options at the other end. The innovative biological options which have been

successful in the management of osteoarthritis include Platelet Rich Plasma (PRP), Bone Marrow Concentrate (BMAC), Autologous Chondrocyte Implantation (ACI).

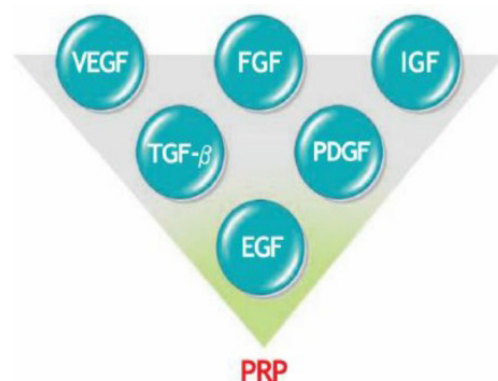
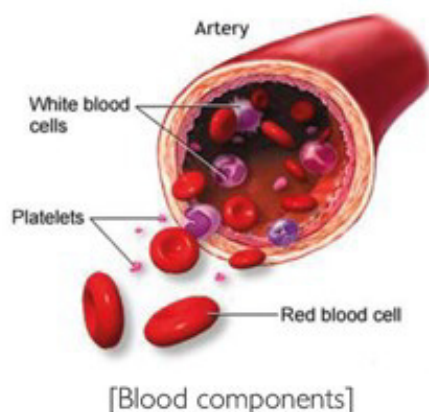
This review describes the role and techniques of these orthobiologics in the management of knee OA along with their potential merits and demerits. This review predominantly focuses on contemporary autologous biologic agents that are being used for the clinical treatment of OA knee along with a comprehensive up-to-date review of published literature.

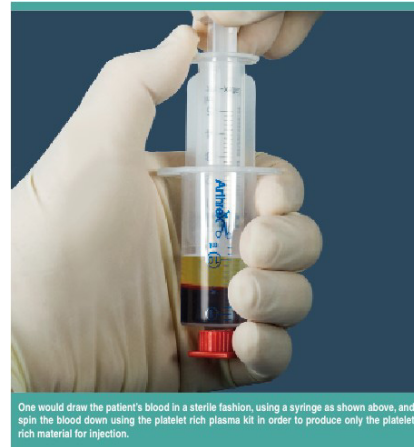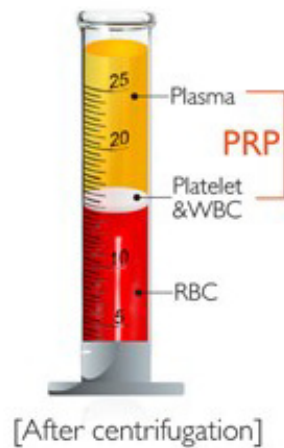
### Platelet Rich Plasma (PRP)

Platelet-Rich Plasma Therapy (PRP) was defined by Arnoczky et al as a sample of autologous blood with

concentrations of platelets in a given volume of plasma that is above the concentration found in whole blood (5). Thus, PRP is autologous blood plasma with concentrated platelets. Typical concentration of platelets in PRP is about 5-10 times that found in whole blood.

Platelets contain natural sources of growth factors, proteins and cytokines that stimulate the healing of bone and soft tissues, such as Platelet-derived growth factor (PDGF), Transforming growth factor beta (TGF- $\beta$ ), Insulin-like growth factor 1 (IGF-1), Insulin-like growth factor 2 (IGF-2), Fibroblast growth factor (FGF), Epidermal growth factor (EGF) and Vascular endothelial growth factor (VEGF).





PRP was first introduced in the 1980s for the treatment of cutaneous ulcers by Margolis et al. Its use was expanded in the 1990s for maxillofacial and plastic surgeries. Its use in orthopaedic surgery began almost a decade ago, and it was initially used with bone grafts to augment spinal fusion and fracture healing. These indications have now expanded widely, with PRP being used to treat tendinopathies and tendon injuries (eg. Lateral epicondylitis or Tennis elbow, Achilles tendinosis, rotator cuff tears etc.), ligamentous injuries and reconstructive surgery (eg. ACL reconstruction), cartilage injuries, osteoarthritis of the knee and hip, muscle injuries and for bone augmentation during fusions and surgeries for non-unions.

Treatment options for early or mild osteoarthritis of the knee include analgesics, activity modification and physiotherapy. Over time, patients usually become refractory to the initial treatment regime, hence reconstructive surgery becomes the subsequent treatment modality. Analgesics only help in reducing inflammation and pain but they are ineffective in delaying the disease progression. In contrast to these treatment options, PRP can shorten the time away from activity, reduce the necessary amount of medication and help avoid invasive treatment with longer recovery times, or speed up the recovery. Thus, PRP injection is an effective and safe treatment for the management of early osteoarthritis and degenerative chondropathy.

**Mechanism of action of PRP:** Platelets stimulate the healing process by the release of growth factors responsible for almost all repair processes that naturally occur in the body. Platelets additionally cause stem cells to activate, another natural healing element responsible for rebuilding damaged tissue. Consequently, new cartilage tissue is formed and healing occurs. PRP therapy accelerates this process by delivering platelets in a concentration 5-10 times that of the normal levels.

PRP also contains fibrinogen, which forms a fibrin scaffold after activation and helps in tissue healing by filling up the cartilage defects. This further augments the biological efficacy of PRP.

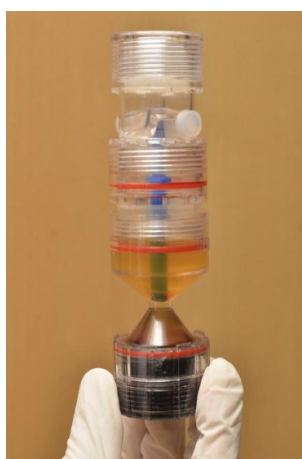**Preparation of PRP:** Aim is to sequester platelets in high concentrations, enough for achieving therapeutic benefit, and in a viable state at the same time, so that they can actively secrete their GFs in the required amount to stimulate repair. Precautions to be taken during this include strict aseptic conditions, optimum temperature regulation (5 – 35o C) and use of an anticoagulant (ACD-A).

I. Sample Collection: 30 cc of venous blood is extracted and 3 cc of ACD-A is added to it.


II. 1st centrifugation at 3200 rpm for 4 minutes.

III. 2nd centrifugation (with the chamber inverted) at 3300 rpm for 3 minutes.

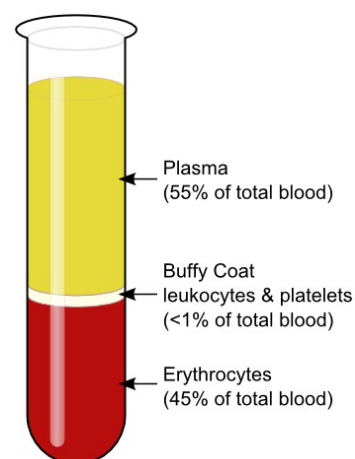
IV: Harvest PRP for use.



1st Cetrifuge

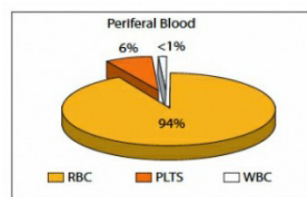


2nd Cetrifuge

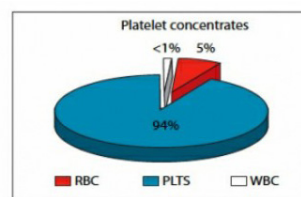


Advantages of PRP: It is a safe, quick and cost-effective procedure, performed easily in an office setting, in a single-stage. Further, the use of autologous blood mitigates the risk of

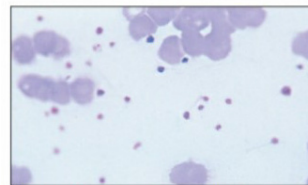
disease transmission or rejection reaction. Proper selection of patients for whom PRP therapy can be beneficial is important.



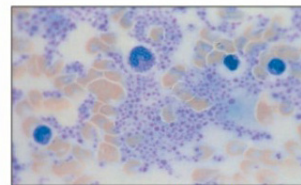
Cell ratios in a normal blood clot.



Cell ratios in platelet rich plasma.



Peripheral blood smear in normal blood.



Peripheral blood smear of platelet rich plasma.

### Results with PRP

In 2010, Sampson et al conducted a study of 14 patients with OA knee. They administered 3 intra-articular injections of PRP 4 weeks apart, and observed significant improvement in pain and Knee Injury scores at 12 months follow-up.

In 2011, Wang-Saegusa et al studied 312 patients with OA knee and treated them with 3 injections of PRP intra-articularly at intervals of 2 weeks. They reported significant improvement in the pain, stiffness and function at 6 months follow-up.

In 2011, Kon et al conducted a randomized controlled trial (RCT) involving 150 patients with early OA of the knee, and compared the clinical outcome after intra-articular injection of PRP, and low and high molecular weight hyaluronic acid. PRP was found to provide longer and better efficacy in reducing pain and symptoms, than both low and high molecular weight HA at 6 months follow up.

In 2012, Spakova et al conducted another RCT with 120 cases of OA knee, 60 of which were given PRP injections and the other 60 were given

HA injections. They found that the pain score and the WOMAC score were statistically better in the PRP group at 6 months follow up.

In 2012, Sanchez et al conducted a multicenter, double-blinded clinical trial to evaluate the safety and efficacy of 3 consecutive weekly intra-articular PRP injections versus HA injections in 176 patients. PRP was found to be superior to HA in reducing knee pain in mild to moderate OA.

In 2014, Anitua et al conducted a systematic review of international peer reviewed literature published between 2008 and 2013 on the efficacy and safety of PRP in knee OA. A total of 530 patients were included by them from 5 different studies, 2 out of which were RCTs, 2 were prospective studies and 1 was a retrospective analysis. They concluded that intra-articular PRP significantly reduced pain and improved function in patients with mild to moderate knee OA.

In 2016, Dai et al performed a meta-analysis of 10 level-I RCTs that evaluated the efficacy of PRP as compared to other modalities for the treatment of early OA knee. A total of

1069 patients were included in the analysis, and they found that PRP and HA showed similar functional outcome (WOMAC and IKDC scores) at 6 months follow-up. However, at 12 months post-injection, PRP was associated with significantly better pain relief and functional improvement (WOMAC and IKDC scores).

In 2017, Martini et al studied 25 patients with grade I and II OA of the knee, and treated them with a single intra-articular injection of PRP. At 6 months follow-up, they found a significant improvement in the VAS, WOMAC and Knee Injury scores, with no adverse reactions in any of the patients.

In 2018, Di Martino et al conducted a double-blind RCT of 192 patients with OA of the knee, studying the efficacy of intra-articular injections of PRP versus HA at 5 years follow-up. They found that a significant reduction in IKDC subjective scores was observed in both treatment groups, with patients in the PRP group presenting significantly higher values compared with the baseline values.

### **Bone Marrow Aspirate Concentrate (BMAC)**

Historically, chondral defects in young patients have been treated with techniques such as microfracture and abrasion chondroplasty. With these techniques, the resulting fibrocartilage production is rich in type I collagen, which may delay the onset of osteoarthritis, but it is structurally inferior to the articular hyaline cartilage. Arthroplasty options are available to those patients who develop end-stage osteoarthritis. Thus, there is a clear demand for regenerative techniques to slow or even reverse this disease process.

Mesenchymal stem cells (MSCs) from bone marrow play a critical role in osteochondral repair. A bone marrow clot forms within the cartilage defect either as a result of marrow stimulation or during the course of the spontaneous repair of osteochondral defects. Mobilized pluripotent MSCs from the subchondral bone migrate into the defect filled with the clot, differentiate into chondrocytes and osteoblasts, and form a repair tissue over time. The additional application of a bone marrow aspirate (BMA) to the procedure of marrow

stimulation is thought to enhance cartilage repair, as marrow itself is both a source of MSCs, providing a cell population capable of chondrogenesis and of various growth factors stimulating cartilage repair. Moreover, the BMA clot provides a three dimensional environment, possibly further supporting chondrogenesis and protecting the subchondral bone from structural alterations.

### **Why use BMA as a source of stem cells?**

Embryonic stem cells are considered the holy grail of stem cells, as they are totipotent and have the potential to differentiate into any cell lineage. But their use is associated with significant ethical issues and considerations, as they require harvest from embryonic tissue.

Adult stem cells are multipotent and can develop into cells that support the tissue of origin. They can be stimulated to irreversibly change their cell lineage in a process termed as transdifferentiation, where cells transform into a different cell type.

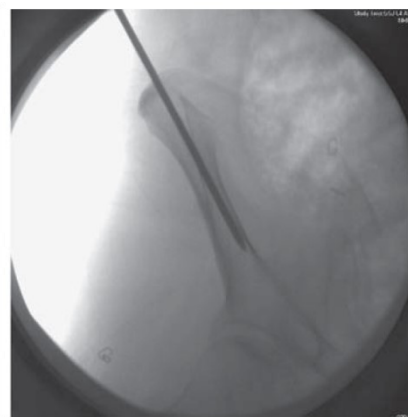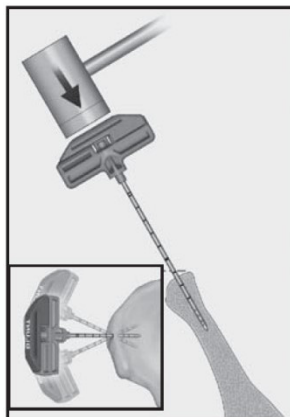
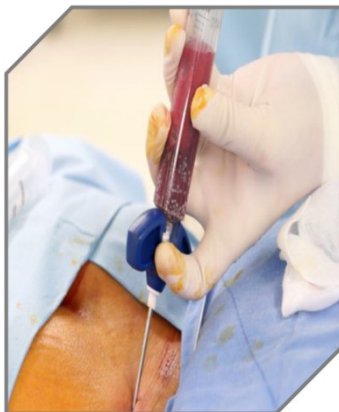MSCs are found not only in bone marrow but also in many other mesenchymal tissues, including

adipose tissue, synovium and blood. However, MSCs from these different mesenchymal tissues differ in their differentiation potential, with those derived from bone marrow being the most multipotent. Also, bone marrow-derived MSCs are innate, they have the appropriate host major histocompatibility complex (MHC) allowing them to avoid destruction by the immune system. Bone marrow aspirate (BMA) is relative easy to harvest, and is a less controversial source of MSCs with the required properties for use in regenerative orthopaedics.

**Need for concentration of BMA:**  
The main concern in using BMA to stimulate tissue repair / regeneration

is that only 0.001% - 0.01% of nucleated cells within BMA are MSCs. To address this issue, various protocols have been developed to concentrate the nucleated cell numbers to produce bone marrow aspirate concentrate (BMAc). Sufficient amount of MSCs are needed to provide an effective environment of healing and regeneration.

Indications for use of BMAc include bone defects / non-unions, AVN particularly of the femoral head, cartilage / osteochondral defects of the knee, talus, etc and tendon injuries such as rotator cuff tears, Achilles tendinopathy. It is a very important first-line treatment option for small symptomatic articular cartilage defects.



### **Preparation of BMAc:**

- I. Aspirate 35 ml bone marrow in a syringe pre-filled with ACD-A. This can

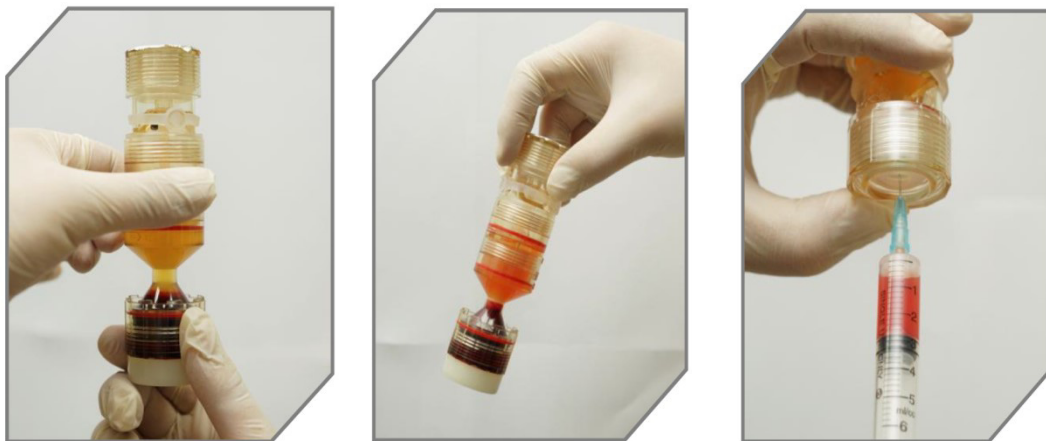be achieved by percutaneous aspiration under local / general anaesthesia from the iliac crest. Trocar placement can be done under fluoroscopy to allow for maximal depth of harvest.

**II.** 1<sup>st</sup> centrifugation at 3500 rpm for 6 minutes.

**III.** Rotate marrow chamber to transfer all buffy coat to plasma chamber.

**IV:** 2<sup>nd</sup> centrifugation after inverting the chamber, at 3300 rpm for 5 minutes.

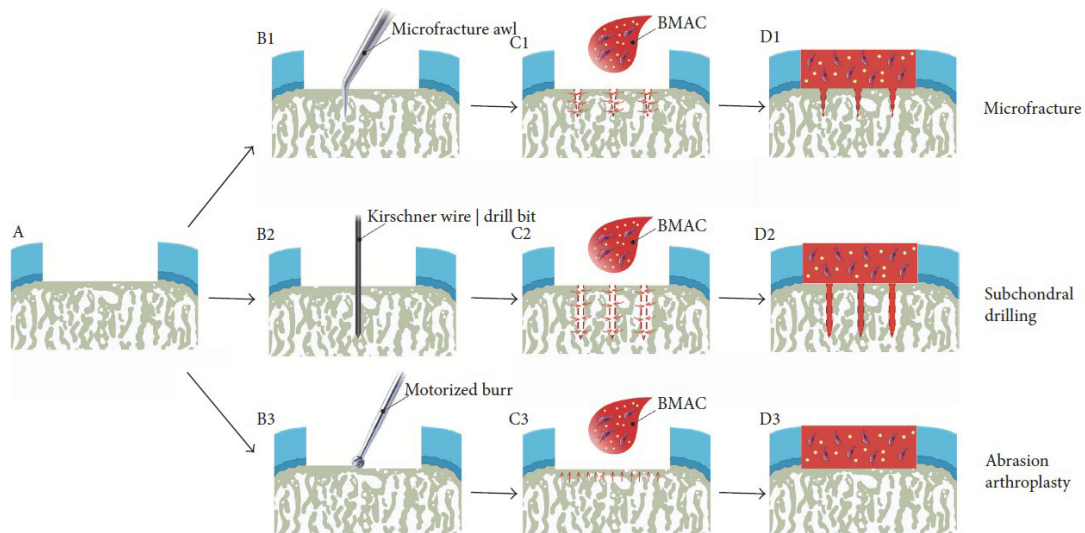
**V.** Harvest BMAC for use.



Technique used for cartilage / osteochondral defects: The basic principle is to establish a communication of the cartilage defect with the subchondral bone marrow compartment. The cartilage defect is surgically prepared by removal of cartilage fragments and generation of stable and vertically oriented margins of the peripheral cartilage. The next

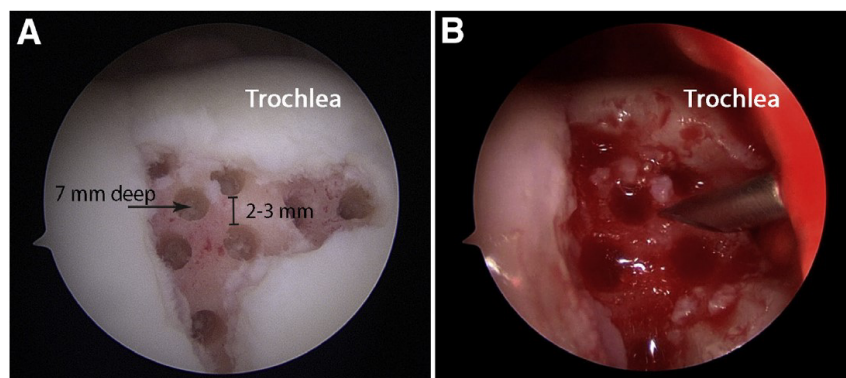
step involves preparation of the bony defect base. The entire layer of calcified cartilage has to be removed, thereby exposing the superficial part of the subchondral bone plate without damaging it.

This is followed by marrow stimulation, performed by microfracture, subchondral drilling or abrasion arthroplasty.



After marrow stimulation, the bone marrow containing mesenchymal stem cells ascends from the marrow cavity of the underlying subchondral bone via the channels generated by the marrow stimulation procedures. These defects are filled with a clot of autologous BMAC, containing mesenchymal stem

cells and growth factors, which favor new tissue formation. Defects thus contain bone marrow both from the subchondral bone and the additional BMAC application, and gradually a cartilaginous repair tissue forms within them.



Trochlea lesion in right knee

(A) Lesion after debridement and drilling. The holes are 7 mm deep and placed 2 to 3 mm apart. (B) The same lesion is injected with BMAC under arthroscopic guidance.

**Advantages:** It is safe as autologous blood is used, thus associated with a lower risk of disease transmission or rejection reaction, and cost-effective. It is also easy to use, effective, and being a single-stage procedure, has better patient satisfaction. Its use may help in avoiding major surgery in the future for OA knees.

**Results with BMAC:** In 2002, Wakitani et al. conducted a study with 2 groups of 12 patients each, with OA knee undergoing high tibial osteotomies. One group received BMAC during surgery and the other served as a control. They found a significant arthroscopic and histological improvement in the BMAC group, but no clinical advantage.

In 2008, Centeno et al. showed that intra-articular injection of BMAC into a knee with symptomatic and radiographic degenerative joint disease resulted in significant cartilage growth, decreased pain and increased joint mobility.

In 2012, Emadedin et al. reported satisfactory improvement in pain and functional status after intra-articular

injection of BMAC in 6 patients with knee OA. They performed an MRI of these patients at 6 months follow up, which demonstrated an increase in cartilage thickness, extension of the repair tissue over the subchondral bone and a considerable decrease in the size of edematous subchondral patches.

In 2013, Orozco et al. conducted another clinico-radiological pilot study and treated 12 patients with OA knee with intra-articular BMAC injection, and evaluated their clinical and radiological (MRI) outcome at 1 year follow up. There was significant improvement both clinically - improvement in pain, disability and quality of life, and, radiologically - highly significant decrease of poor cartilage areas along with improvement of cartilage quality in 11 of the 12 patients.

In 2014, Kim et al. evaluated the clinical efficacy of intra-articular injection of BMAC with adipose tissue in 41 patients with OA knee. There was improvement in both the pain VAS score and the functional scores (IKDC, SF-36, Lysholm Knee Questionnaire) at 12 months follow-up.

In 2016, Chahla et al. performed a systematic review of 11 studies on the outcomes of bone marrow aspirate concentrate for the treatment of chondral defects and osteoarthritis of the knee. Of these, 5 were prospective studies, 1 was a retrospective study, 2 were case series, and 3 were case reports. They reported good to excellent overall outcomes with the use of BMAC for the treatment of early knee osteoarthritis and moderate focal chondral defects.

In 2017, Moatshe et al. conducted another systematic review of studies on the efficacy of the biologic treatments utilized in knee pathologies, including PRP and BMAC. They found

that, although most of these studies showed good clinical and functional outcomes with the use of these techniques, with an acceptable safety profile, they lack enough power and follow-up time for the evidence to be compelling.

In 2018, Themistocleous et al. performed a study of 233 patients with idiopathic OA of the knee, treated with a single intra-articular BMAC injection. At a mean follow-up period of 11 months, they reported that the patients showed significant clinical and functional improvement with respect to the Numeric Pain Scale and the Oxford Knee Score. They found no complication in any patient.

## Conclusion

To summarize, many important advancements have been made in Orthobiologics and these therapies are still evolving. We need a clear understanding of the basic underlying pathology of OA and the mechanism by which these Orthobiologics can be helpful. Osteoarthritis is a multifaceted disease involving not only the hyaline cartilage but also fibrous capsule, meniscus and the subchondral bone as the other variables of OA knee such as limb malalignment, ligamentous insufficiency and muscular imbalances have to be considered. Most of the studies suggest good outcomes with using Orthobiologics (PRP, BMAC) but they lack enough power and follow up. We need clear understanding of the graft choice and patient selection in the treatment of early OA. In order to achieve this, we suggest the need for conducting further well designed randomized control trials with definite protocols to elucidate the real efficacy of these therapies.

## Bibliography

### BMP's in Orthopaedics

1. Urist MR, Mikulski AJ, Nakagawa M, Yen K (1977) A bone matrix calcification-initiator noncollagenous protein. *Am J Physiol* 232(3): C115–C127
2. Bishop GB, Einhorn TA (2007) Current and future clinical applications of bone morphogenetic proteins in orthopaedic trauma surgery. *Int Orthop* 31(6):721–727. doi:10.1007/s00264-007-0424-8
3. Lissenberg-Thunnissen SN, de Gorter DJ, Sier CF, Schipper IB (2011) Use and efficacy of bone morphogenetic proteins in fracture healing. *Int Orthop* 35(9):1271–1280. doi:10.1007/s00264-011-1301-z
4. Vukicevic S, Oppermann H, Verbanac D, Jankolija M, Popek I, Curak J, Brkljacic J, Pauk M, Erjavec I, Francetic I, Dumic-Cule I, Jelic M, Durdevic D, Vlahovic T, Novak R, Kufner V, Bordukalo Niksic T, Kozlovic M, Banic Tomisic Z, Bubic-Spoljar J, Bastalic I, Vikić-Topic S, Peric M, Pecina M, Grgurevic L (2014) The clinical use of bone morphogenetic proteins revisited: a novel biocompatible carrier device OSTEOGROW for bone healing. *Int Orthop* 38(3): 635–647. doi:10.1007/s00264-013-2201-1
5. Fu R, Selph S, McDonagh M, Peterson K, Tiwari A, Chou R, Helfand M (2013) Effectiveness and harms of recombinant human bone morphogenetic protein-2 in spine fusion: a systematic review and meta-analysis. *Ann Intern Med* 158 (12):890-902. doi:10.7326/0003-4819-158-12-201306180-00006
6. Simmonds MC, Brown JV, Heirs MK, Higgins JP, Mannion RJ, Rodgers MA, Stewart LA (2013) Safety and effectiveness of recombinant human bone morphogenetic protein-2 for spinal fusion: a meta-analysis of individual-participant data. *Ann Intern Med* 158 (12):877-889. doi:10.7326/0003-4819-158-12-201306180-00005
7. Delimar D, Smoljanovic T, Bojanic I (2012) Could the use of bone morphogenetic proteins in fracture healing do more harm than good to our patients? *Int Orthop* 36 (3):683; author reply 685. doi:10.1007/s00264-011-1397-1
8. Bong MR, Capla EL, Egol KA, Sorkin AT, Distefano M, Buckle R, Chandler RW, Koval KJ (2005) Osteogenic protein-1 (bone morphogenetic protein-7) combined with various adjuncts in the treatment of humeral diaphyseal nonunions. *Bull Hosp Jt Dis* 63(1–2): 20–23
9. Dimitriou R, Dahabreh Z, Katsoulis E, Matthews SJ, Branfoot T, Giannoudis PV

- (2005) Application of recombinant BMP-7 on persistent upper and lower limb non-unions. *Injury* 36 Suppl 4:S51-59. doi:10.1016/j.injury.2005.10.010
10. Moghaddam A, Elleser C, Biglari B, Wentzensen A, Zimmermann G (2010) Clinical application of BMP 7 in long bone non-unions. *Arch Orthop Trauma Surg* 130(1):71–76. doi:10.1007/s00402-009-0982-x
11. Ronga M, Baldo F, Zappala G, Cherubino P (2006) Recombinant human bone morphogenetic protein-7 for treatment of long bone non-union: an observational, retrospective, non-randomized study of 105 patients. *Injury* 37 Suppl 3:S51-56. doi:10.1016/j.injury.2006.08.024
12. Evans RO, Goldberg JA, Bruce WJ, Walsh W (2004) Reoperated clavicular nonunion treated with osteogenic protein 1 and electrical stimulation. *J Shoulder Elbow Surg* 13 (5):573-575. doi:10.1016/S105827460400076X
13. Clark RR, McKinley TO (2010) Bilateral olecranon epiphyseal fracture non-union in a competitive athlete. *Iowa Orthop J* 30: 179–181
14. Friedlaender GE, Perry CR, Cole JD, Cook SD, Cierny G, Muschler GF, Zych GA, Calhoun JH, LaForte AJ, Yin S (2001) Osteogenic protein-1 (bone morphogenetic protein-7) in the treatment of tibial nonunions. *J Bone Joint Surg Am* 83-A Suppl 1(Pt 2):S151–S158
15. Zimmermann G, Wagner C, Schmeckenbecher K, Wentzensen A, Moghaddam A (2009) Treatment of tibial shaft non-unions: bone morphogenetic proteins versus autologous bone graft. *Injury* 40 Suppl 3:S50-53. doi:10.1016/S0020-1383(09)70012-9
16. Kanakaris NK, Calori GM, Verdonk R, Burssens P, De Biase P, Capanna R, Vangosa LB, Cherubino P, Baldo F, Ristiniemi J, Kontakis G, Giannoudis PV (2008) Application of BMP-7 to tibial non-unions: a 3-year multicenter experience. *Injury* 39 Suppl 2:S83- 90. doi:10.1016/S0020-1383(08)70019-6
17. Obert L, Deschaseaux F, Garbuio P (2005) Critical analysis and efficacy of BMPs in long bones non-union. *Injury* 36 Suppl 3:S38- 42. doi:10.1016/j.injury.2005.07.033
18. Wysocki RW, Cohen MS (2007) Ectopic ossification of the triceps muscle after application of bone morphogenetic protein-7 to the distal humerus for recalcitrant nonunion: a case report. *J Hand Surg Am* 32 (5):647-650. doi:10.1016/j.jhssa.2007.03.001
19. Boraiah S, Paul O, Hawkes D, Wickham M, Lorch DG (2009) Complications of recombinant human BMP-2 for treating complex tibial plateau

- fractures: a preliminary report. *Clin Orthop Relat Res* 467(12):3257–3262. doi:10.1007/s11999-009-1039-8
20. Bilic R, Simic P, Jelic M, Stern-Padovan R, Dodig D, van Meerdervoort HP, Martinovic S, Ivankovic D, Pecina M, Vukicevic S (2006) Osteogenic protein-1 (BMP-7) accelerates healing of scaphoid non-union with proximal pole sclerosis. *Int Orthop* 30(2):128–134. doi:10.1007/s00264-005-0045-z
  21. Bibbo C, Patel DV, Haskell MD (2009) Recombinant bone morphogenetic protein-2 (rhBMP-2) in high-risk ankle and hindfoot fusions. *Foot Ankle Int* 30 (7):597-603. doi:10.3113/FAI.2009.0597
  22. Schuberth JM, DiDomenico LA, Mendicino RW (2009) The utility and effectiveness of bone morphogenetic protein in foot and ankle surgery. *J Foot Ankle Surg* 48 (3):309-314. doi:10.1053/j.jfas.2009. 01.011
  23. El-Amin SF, Hogan MV, Allen AA, Hinds J, Laurencin CT (2010) The indications and use of bone morphogenetic proteins in foot, ankle, and tibia surgery. *Foot Ankle Clin* 15 (4):543-551. doi:10. 1016/j.fcl.2010.08.001
  24. Fourman MS, Borst EW, Bogner E, Rozbruch SR, Fragomen AT (2014) Recombinant Human BMP-2 Increases the Incidence and Rate of Healing in Complex Ankle Arthrodesis. *Clin Orthop Relat Res* 472(2):732–739. doi:10.1007/s11999-013-3261-7
  25. Hawkins BJ (2010) Biologics in foot and ankle surgery. *Foot Ankle Clin* 15 (4):577-596. doi:10.1016/j.fcl.2010.07.003
  26. DeVries JG, Nguyen M, Berlet GC, Hyer CF (2012) The effect of recombinant bone morphogenetic protein-2 in revision tibiototalcalcaneal arthrodesis: utilization of the Retrograde Arthrodesis Intramedullary Nail database. *J Foot Ankle Surg* 51 (4):426-432. doi:10.1053/j.jfas. 2012.03.007
  27. Kanakaris NK, Mallina R, Calori GM, Kontakis G, Giannoudis PV (2009) Use of bone morphogenetic proteins in arthrodesis: clinical results. *Injury* 40 Suppl 3:S62-66. doi:10.1016/S0020-1383(09) 70014-2S0020-1383 (09) 70014-2
  28. Pecina M, Jelic M, Martinovic S, Haspl M, Vukicevic S (2002) Articular cartilage repair: the role of bone morphogenetic proteins. *Int Orthop* 26(3):131–136. doi:10.1007/s00264-002-0338-4
  29. Tannoury C, An HS (2014) Complications with Use of Bone Morphogenetic Protein-2 (BMP-2) in Spine Surgery. *Spine J.* doi: 10.1016/j.spinee.2013.08.060
  30. Singh K, Ahmadinia K, Park DK, Nandyala SV, Marquez-Lara A, Patel AA,

- Fineberg SJ (2014) Complications of spinal fusion with utilization of bone morphogenetic protein: a systematic review of the literature. *Spine (Phila Pa 1976)* 39(1):91–101. doi:10.1097/BRS.0000000000000004
31. Vaidya R, Sethi A, Bartol S, Jacobson M, Coe C, Craig JG (2008) Complications in the use of rhBMP-2 in PEEK cages for interbody spinal fusions. *J Spinal Disord Tech* 21 (8):557–562. doi:10.1097/BSD.0b013e31815ea897
32. Balseiro S, Nottmeier EW (2010) Vertebral osteolysis originating from subchondral cyst end plate defects in transforaminal lumbar interbody fusion using rhBMP-2. Report of two cases. *Spine J* 10 (7): e6–e10. doi:10.1016/j.spinee.2010.04.013
33. Helgeson MD, Lehman RA, Jr., Patzkowski JC, Dmitriev AE, Rosner MK, Mack AW (2011) Adjacent vertebral body osteolysis with bone morphogenetic protein use in transforaminal lumbar interbody fusion. *Spine J* 11 (6):507–510. doi:10.1016/j.spinee. 2011.01.017
34. Saigal G, Quencer R, Guest JD, Cristescu MM, Lebwohl N (2012) Vertebral body osteolysis following the use of bone morphogenetic protein in spinal surgery: a mimicker of infection. *J Neuroradiol* 39 (5):354–359. doi:10.1016/j.neurad. 2012.03.005
35. Smoljanovic T, Bojanic I, Cemic M (2009) Bone morphogenetic protein. *J Neurosurg Spine* 11 (1):92–93; author reply 93–94. doi: 10.3171/2009.2.SPINE08953L
36. Deutsch H (2010) High-dose bone morphogenetic protein-induced ectopic abdomen bone growth. *Spine J* 10 (2):e1–4. doi:10.1016/j. spinee.2009.10.016
37. Anderson CL, Whitaker MC (2012) Heterotopic ossification associated with recombinant human bone morphogenetic protein-2 (infuse) in posterolateral lumbar spine fusion: a case report. *Spine (Phila Pa 1976)* 37(8):E502–E506. doi:10.1097/BRS.0b013e318238870b
38. Joseph V, Rampersaud YR (2007) Heterotopic bone formation with the use of rhBMP2 in posterior minimal access interbody fusion: a CT analysis. *Spine (Phila Pa 1976)* 32 (25):2885–2890. doi:10.1097/BRS.0b013e31815b7596
39. Chen NF, Smith ZA, Stiner E, Armin S, Sheikh H, Khoo LT (2010) Symptomatic ectopic bone formation after off-label use of recombinant human bone morphogenetic protein-2 in transforaminal lumbar interbody fusion. *J Neurosurg Spine* 12(1):40–46. doi:10.3171/2009.4.SPINE0876
40. Glassman SD, Gum JL, Crawford CH, 3rd, Shields CB, Carreon LY (2011) Complications with recombinant human

- bone morphogenetic protein-2 in posterolateral spine fusion associated with a dural tear. *Spine J* 11 (6):522-526. doi:10.1016/j.spinee.2010.05.016
41. Choudhry OJ, Christiano LD, Singh R, Golden BM, Liu JK (2012) Bone morphogenetic protein-induced inflammatory cyst formation after lumbar fusion causing nerve root compression. *J Neurosurg Spine* 16(3):296–301. doi:10.3171/2011.11.SPINE11629
42. Smucker JD, Rhee JM, Singh K, Yoon ST, Heller JG (2006) Increased swelling complications associated with off-label usage of rhBMP-2 in the anterior cervical spine. *Spine (Phila Pa 1976)* 31 (24):2813-2819. doi:10.1097/01.brs.0000245863.52371.c2
43. Perri B, Cooper M, Lauryssen C, Anand N (2007) Adverse swelling associated with use of rh-BMP-2 in anterior cervical discectomy and fusion: a case study. *Spine J* 7 (2):235-239. doi:10.1016/j.spinee.2006.04.010
44. Shahlaie K, Kim KD (2008) Occipitocervical fusion using recombinant human bone morphogenetic protein-2: adverse effects due to tissue swelling and seroma. *Spine (Phila Pa 1976)* 33 (21):2361- 2366. doi:10.1097/BRS.0b013e318183971d
45. Anticevic D, Jelic M, Vukicevic S (2006) Treatment of a congenital pseudarthrosis of the tibia by osteogenic protein-1 (bone morphogenetic protein-7): a case report. *J Pediatr Orthop B* 15 (3):220-221. doi: 10.1097/01.bpb.0000194439.75378.ac
46. Spiro AS, Babin K, Lipovac S, Stenger P, Mladenov K, Rupprecht M, Rueger JM, Stuecker R (2011) Combined treatment of congenital pseudarthrosis of the tibia, including recombinant human bone morphogenetic protein-2: a case series. *J Bone Joint Surg Br* 93 (5):695- 699. doi:10.1302/0301-620X.93B5.25938
47. Pannier S (2011) Congenital pseudarthrosis of the tibia. *Orthop Traumatol Surg Res* 97 (7):750-761. doi:10.1016/j.otsr.2011.09.001
48. Richards BS, Oetgen ME, Johnston CE (2010) The use of rhBMP-2 for the treatment of congenital pseudarthrosis of the tibia: a case series. *J Bone Joint Surg Am* 92 (1):177-185. doi:10.2106/JBJS.H.01667
49. Cheng TL, Murphy CM, Cantrill LC, Mikulec K, Carpenter C, Schindeler A, Little DG (2014) Local delivery of recombinant human bone morphogenetic proteins and bisphosphonate via sucrose acetate isobutyrate can prevent femoral head collapse in Legg-Calve-Perthes disease: a pilot study in pigs. *Int Orthop* 38(7):1527–1533. doi:10. 1007/s00264-013-2255-0

50. Steib JP, Bouchaib J, Walter A, Schuller S, Charles YP (2010) Could an osteoinductor result in degeneration of a neurofibroma in NF1? *Eur Spine J* 19(Suppl 2):S220–S225. doi:10.1007/s00586-010-1416-8

### **Platelet biology and introduction to Platelet Rich Plasma**

1. Malanga GA, Goldin M. PRP: review of the current evidence for musculoskeletal conditions. *Curr Phys Med Rehabil Rep* 2014;2:1–5.
2. Davis VL, Abukabda AB, Radio NM, et al. Platelet-rich preparations to improve healing. Part I: workable options for every size practice. *J Oral Implantol* 2014; 40(4):500–10.
3. Boswell SG, Cole BJ, Sundman EA, et al. Platelet-rich plasma: a milieu of bioactive factors. *Arthroscopy* 2012;28(3):429–39.
4. Blair P, Flaumenhaft R. Platelet alpha-granules: basic biology and clinical correlates. *Blood Rev* 2009;23(4):177–89.
5. Hoemann CD, Chen G, Marchand C, et al. Scaffold-guided subchondral bone repair: implication of neutrophils and alternatively activated arginase-11 macrophages. *Am J Sports Med* 2010;38(9):1845–56.
6. 14. Assirelli E, Filardo G, Mariani E, et al. Effect of two different preparations of platelet-rich plasma on synoviocytes. *Knee Surg Sports Traumatol Arthrosc* 2015;23(9):2690–703.
7. Braun HJ, Kim HJ, Chu CR, et al. The effect of platelet-rich plasma formulations and blood products on human synoviocytes: implications for intra-articular injury and therapy. *Am J Sports Med* 2014;42(5):1204–10.
8. Javier Ramos-Torrecillas, Elvira De Luna-Bertos, Olga García-Martínez, Concepción Ruiz. Clinical Utility of Growth Factors and Platelet-Rich Plasma in Tissue Regeneration: A Review. *WOUNDS*. 2014;26(7):207-213.
9. Peter I-Kung Wu, Robert Diaz, Joanne Borg-Stein. Platelet-Rich Plasma, *Phys Med Rehabil Clin N Am* 27 (2016) 825–853.
10. Platelet Rich Plasma (PRP) Guidelines, © International Cellular Medicine Society – 2011. Available at [www.cellmedicinesociety.org](http://www.cellmedicinesociety.org).
11. Shetty VD, Dhillon M, Hegde C, Jagtap P, Shetty S. A study to compare the efficacy of corticosteroid therapy with platelet-rich plasma therapy in recalcitrant plantar fasciitis: a preliminary report. *Foot Ankle Surg*. 2014; 20(1):10-13.
12. Kumar V, Millar T, Murphy PN, Clough T. The treatment of intractable planter fasciitis with platelet-rich plasma injection.

Foot (Edinb). 2013; 23:74-77.

14.F. SAY, E. TÜRKEİ, M. BÜLBÜL. Is Platelet-Rich Plasma Injection an Effective Choice in Cases of Non-Union? . *Actachirurgiae orthopaedicae et traumatologiae Cechoslovaca* 2014.81(5):340-345 .

15. Mishra A, Pavelko T (2006) Treatment of chronic elbow tendinosis with buffered platelet-rich plasma. *Am J Sports Med*; 34:1774–1778.

16. Sebastian Lippross, Mauro Alini. Platelet-rich plasma for bone healing— to use or not to use? Available at <https://pdfs.semanticscholar.org/62e7/d0bcf3f92248aa4f0606b0c8a8f3de695536.pdf>.

17.Dhillon MS, Behera P, Patel S, Shetty V. Orthobiologics and platelet rich plasma. *Indian J Orthop* 2014;48:1-9.

#### **Platelet Rich Plasma extraction with low cost assembled kit.**

1.Eduardo Anitua, Roberto Prado, Mikel Sánchez, Gorka Orive. Platelet-Rich Plasma: Preparation and Formulation. *Oper Tech Orthop* ; 2012;22:25-32.

2. Alsousou.j, Thompson.M, Hulley.p, Noble.A, Willett.K. The biology of platelet-rich plasma and its application in trauma and orthopaedic surgery. *J Bone Joint Surg [Br]*2009;91-B:987-96.

3.Marx RE. Platelet-rich plasma (PRP): what is PRP and what is not PRP? *Implant Dent*. 2001;10:225-8.

4.Augustus D. Mazzocca, Mary Beth R. McCarthy, David M. Chowanec, Mark P. Cote, Anthony A. Romeo, James P. Bradley et al. Platelet-Rich Plasma Differs According to Preparation Method and Human Variability. *Bone Joint Surg Am*. 2012;94:308-16.

5.Platelet Rich Plasma (PRP) guidelines, international cellular medicine society.2011[ last accessed 2016 sept 10]. Available from:<http://www.cellmedicinesociety.org>.

6.Paola Romina Amable,Rosana Bizon Vieira Carias,Marcus Vinicius Telles Teixeira,Ítalo da Cruz Pacheco,Ronaldo José Farias Corrêa do Amaral,José Mauro Granjeiro et al. Platelet-rich plasma preparation for regenerative medicine: optimization and quantification of cytokines and growth factors. *Stem Cell Research & Therapy*2013;4:67-78.

7. Han-tung Liao, Kacey Marra,J Peter Rubin.Application of platelet –rich plasma and platelet rich fibrin in fat grafting:basic science and literature review.*tissue engineering*2014;20(4):267-72.

8.Amanda G. M. Perez, José Fábio S. D. Lana, Ana Amélia Rodrigues, Angela Cristina M. Luzo, William D. Belangero,

- Maria Helena A. Santana. Relevant Aspects of Centrifugation Step in the Preparation of Platelet-Rich Plasma. ISRN Hematology 2014;1-8.
- 9.Olivier Bausset, Laurent Giraudo, Julie Veran, Jeremy Magalon, Jean-Marie Coudreuse, Guy Magalon et al . Formulation and Storage of Platelet-Rich Plasma Homemade Product. BioResearch Open Access 2012;1:115-21.
- 10.Yavuz kecec, sibel ozsu, Oktay bilgar. A cost effective method for obtaining standard platelet rich plasma. wounds 2014;28(8):232-8.
- 11.S.J Slichter. Harker. Preparation and storage of platelet concentrates:1. Factors influencing the harvest of viable platelets from whole blood. Br J Haematol 1976;34(3):395-402.
- 12.Jennifer E. Woodell-May, Dayna N. Ridderman, Matthew J. Swift, Joel Higgins. Producing Accurate Platelet Counts for Platelet Rich Plasma: Validation of a Hematology Analyzer and Preparation Techniques for Counting. The journal of craniofacial surgery 2005; 16(5):749-56.
- 13.Schneider bs, Tiidus pp. neutrophil infiltration in exercise injured skeletal muscle. Sportsmed 2007;37:837-56.
- 14.Michael p Hall, Phillip A Band, Robert J Meislin, Laith M Jazrawi, Dennis A Cardone. Platelet rich plasma: current concepts and application in sports medicine. J AAOS 2009;17(10):602-8.
- 15.Mototsugu Fukaya, Asako Ito. A new economic method for preparing platelet – rich plasma . J PRSGO. 2014;1-7.
16. Masoomah Gholami, Hamid Ravaghi, Masoud Salehi, Amirhosein Abedi Yekta, Shila Doaee, Ebrahim Jaafari pooyan. A systematic review and meta-analysis of the application of platelet rich plasma in sports medicine. Electronic Physician 2016; 8:2325-32.

#### Platelet-rich plasma therapy in tendinopathies

1. Scher D, Jr Belmont P, Owens B, . The epidemiology of plantar fasciitis, LER, April 2010; www.ler magazine.com
2. Alves R. Grimalt R. A Review of Platelet-Rich Plasma: History, Biology, Mechanism of Action, and Classification Skin Appendage Disord 2018;4:18–24
3. Magalon J, Bausset O, Serratrice N, et al. Characterization and comparison of 5 platelet-rich plasma preparations in a single-donor model. Arthroscopy. 2014; 30: 629–638
4. Blajchman M. Novel platelet products, substitutes and alternatives. Transfus Clin Biol. 2001; 8:267–271

5. Dragoo J, Braun H, Durham J, Ridley B, Odegaard J, Luong R, Arnoczky S. Comparison of the acute inflammatory response of two commercial platelet-rich plasma systems in healthy rabbit tendons. *Am J Sports Med.* 2012;40:1274–1281
6. Adrian D, Lawrence E, Malcolm R, and Jason L. Dragoo J. Current Clinical Recommendations for the use of Platelet-Rich Plasma. *Curr Rev Musculoskelet Med.* 2018 Dec; 11(4): 624–634
7. Arirachakaran A, Sukthuyat A, Sisayanarane T, Laoratanavoraphong S, Kanchanatawan W, Kongtharvonskul J. Platelet-rich plasma versus autologous blood versus steroid injection in lateral epicondylitis: a systematic review and network meta-analysis. *J Orthop Traumatol.* 2016;17:101–112
8. Krogh T, Bartels E, Ellingsen T, Stengaard-Pedersen K, Buchbinder R, Fredberg U, Bliddal H, Christensen R. Comparative effectiveness of injection therapies in lateral epicondylitis: a systematic review and network meta-analysis of randomized controlled trials. *Am J Sports Med.* 2013;41:1435–1446
9. Dragoo J, Wasterlain A, Braun H, Nead K. Platelet-rich plasma as a treatment for patellar tendinopathy: a double-blind, randomized controlled trial. *Am J Sports Med.* 2014;42:610–618
10. Shetty V, Dhillon M, Hegde C, Jagtap P, Shetty S. A study to compare the efficacy of corticosteroid therapy with platelet-rich plasma therapy in recalcitrant plantar fasciitis: a preliminary report. *Foot Ankle Surg.* 2014;20:10–13
11. Mahindra P, Yamin M, Selhi H, Singla S, Soni A. Chronic plantar fasciitis: effect of platelet-rich plasma, corticosteroid, and placebo. *Orthopedics.* 2016;39:e285–e289
12. Monto R. Platelet-rich plasma efficacy versus corticosteroid injection treatment for chronic severe plantar fasciitis. *Foot Ankle Int.* 2014;35:313–318
13. Yang W, Han Y, Cao X, Pan J, Zeng L, Lin J, et al. Platelet-rich plasma as a treatment for plantar fasciitis: a meta-analysis of randomized controlled trials. *Medicine (Baltimore)* 2017;96:e8475
14. Singh P, Madanipour S, Bhamra J, Gill I. A systematic review and meta-analysis of platelet-rich plasma versus corticosteroid injections for plantar fasciopathy. *Int Orthop.* 2017;41:1169–1181
15. de Vos RJ, Weir A, Tol J, Verhaar J, Weinans H, van Schie H. No effects of PRP on ultrasonographic tendon structure and neovascularisation in chronic midportion Achilles tendinopathy. *Br J Sports Med.* 2011;45:387–392

**PRP in OA Knee: Consensus Document**

1. Buckwalter JA, Mankin HJ (1997) Articular cartilage: degeneration and osteoarthritis, repair, regeneration, and transplantation. *J Bone Joint Surg Am* 79A(4):612–632.
2. Gobbi A (2010) New possibilities for cartilage repair. *Eur Musculoskelet Rev* 5(2):64–68
3. Tran-Khanh N, Hoemann CD, McKee MD, Henderson JE, Buschmann MD (2005) Aged bovine chondrocytes display a diminished capacity to produce a collagen-rich, mechanically functional cartilage extracellular matrix. *J Orthop Res* 23:1354–1362
4. Pietrzak WS, Eppley BL (2007) Platelet rich plasma: biology and new technology. *J Craniofac Surg* 16(6):1043–1054
5. Frisbie DD, Kawcak CE, Werpy NM, Park RD, McIlwraith CW (2007) Clinical, biochemical, and histologic effects of intra-articular administration of autologous conditioned serum in horses with experimentally induced osteoarthritis. *Am J Vet Res* 68:290–296
6. Treatment With Platelet-Rich Plasma Is More Effective Than Placebo for Knee Osteoarthritis A Prospective, Double-Blind, Randomized Trial Sandeep Patel , Mandeep S. Dhillon, Sameer Aggarwal, Neelam Marwaha, Ashish Jain, MD. The

American Journal of Sports Medicine, Vol. XX, No. X DOI: 10.1177/0363546512471299 2013

**Bone Marrow Aspirate Concentrate**

1. Arianna L Gianakos, Li Sun, JayN Patel, Donald M Adams, Frank A Liporace. Clinical application of concentrated bone marrow aspirate in orthopaedics: A systemic review. *World J Orthop* 2017.8(6):491-506.
2. Jorge Chahla, Sandeep M, Mark E cinque et al. bone marrow aspirate concentrate harvesting and processing technique. *Arthroscopy Techniques* 2017.6(2):441-5.
3. Mohammed A. Imam, Samer S Smahumoud et al. A systematic review of the concept and clinical applications of bone marrow Aspirate Concentrate in Orthopaedics. *SICOT j* 2017.3:17.
4. Centeno C, Pitts J, Al-sayegh H, Freeman M. Efficacy of autologous bone marrow concentrate for knee osteoarthritis with and without adipose graft. *Biomed Res Int.* 2014:370621.
5. Hauser RA, Orlofsky A. Regenerative injection therapy with whole bone marrow aspirate for degenerative joint diseases : a case series. *Clin Med Insights Arthritis Musculoskeletal disord.* 2013;6:65-72.
6. Kim JD, Lee GW, Jung GH et al. clinical outcome of autologous bone marrow

aspirate concentrate(BMAC) injection in degenerative arthritis of the knee. *Eur J OrthopSurg Traumatol.*2014;24:1505-11.

7. Hernigou P, Mathieu G, Poignard A, Manicom O, Manicom O, Beaujean F, Beaujean F, Rouard H (2006) Percutaneous autologous bone-marrow grafting for nonunions. Surgical technique. *J Bone Joint Surg Am* 88, 322–327

8. Hernigou P, Beaujean F (2002) Treatment of osteonecrosis with autologous bone marrow grafting. *ClinOrthopRelat Res* 405, 14–23.

9.Giannini S, Buda R, Cavallo M, Ruffili A, Cenacchi A, Cavallo C, Vannini F (2010) Cartilage repair evolution in posttraumatic osteochondral lesions of the talus: from open eld autologous chondrocyte to bone-marrow-derived cells transplantation. *Injury* 41(11), 1196–1203.

10.Hernigou P, FlouzatLachaniette CH, Delambre J, Zilber S, Dufet P, Chevallier N, Rouard H (2014) Biologic augmentation of rotator cuff repair with mesenchymal stem cells during arthroscopy improves healing and prevents further tears: a casecontrolled study. *IntOrthop* 38(9), 1811–1818.

#### **BMAC in Non Union of Fractures**

1. Bastos Filho R, Lermontov S, Borojevic R, Schott PC, Gameiro VS, Granjeiro JM. Cell therapy of pseudarthrosis. *Acta Ortop Bras* 2012;

20: 270-273 [PMID: 24453616 DOI: 10.1590/S1413-7852 2012000500005]

2. Desai P, Hasan SM, Zambrana L, Hegde V, Saleh A, Cohn MR, Lane JM. Bone Mesenchymal Stem Cells with Growth Factors Successfully Treat Nonunions and Delayed Unions. *HSS J* 2015; 11: 104-111 [PMID: 26140028 DOI: 10.1007/s11420-015-9432-1]

3. Garnavos C, Mouzopoulos G, Morakis E. Fixed intramedullary nailing and percutaneous autologous concentrated bone-marrow grafting can promote bone healing in humeral-shaft fractures with delayed union. *Injury* 2010; 41: 563-567 [PMID: 19740464 DOI: 10.1016/j.injury.2009.08.003]

4. Guimarães JA, Duarte ME, Fernandes MB, Vianna VF, Rocha TH, Bonfim DC, Casado PL, do Val Guimarães IC, Velarde LG, Dutra HS, Giannoudis PV. The effect of autologous concentrated bonemarrow grafting on the healing of femoral shaft non-unions after locked intramedullary nailing. *Injury* 2014; 45 Suppl 5: S7-S13 [PMID: 25528626 DOI: 10.1016/S0020-1383(14)70013-0]

5. Hernigou P, Guissou I, Homma Y, Poignard A, Chevallier N, Rouard H, Flouzat Lachaniette CH. Percutaneous injection of bone marrow mesenchymal stem cells for ankle non-unions decreases complications in patients with diabetes. *Int*

Orthop 2015; 39: 1639-1643 [PMID: 25795249 DOI: 10.1007/s00264-015-2738-2]

6. Hernigou P, Poignard A, Beaujean F, Rouard H. Percutaneous autologous bone-marrow grafting for nonunions. Influence of the number and concentration of progenitor cells. *J Bone Joint Surg Am* 2005; 87: 1430-1437 [PMID: 15995108 DOI:10.2106/JBJS.D.02215]

7. Ismail HD, Phedy P, Kholinne E, Djaja YP, Kusnadi Y, Merlina M, Yulisa ND. Mesenchymal stem cell implantation in atrophic non-union of the long bones: A translational study. *Bone Joint Res* 2016; 5: 287-293 [PMID: 27412657 DOI: 10.1302/2046-3758.57.2000587]

8. Le Nail LR, Stanovici J, Fournier J, Splingard M, Domenech J, Rosset P. Percutaneous grafting with bone marrow autologous concentrate for open tibia fractures: analysis of forty three cases and literature review. *Int Orthop* 2014; 38: 1845-1853 [PMID: 24728310 DOI: 10.1007/s00264-014-2342-x]

#### **Mesenchymal Stem Cells in Management of Avascular Necrosis Femur Head**

1. Sen RK. Management of avascular necrosis of femoral head at pre-collapse stage. *Indian J Orthop*. 2009;43(1):6-16.  
2. Tripathy SK, Goyal T, Sen RK. Management of femoral head

osteonecrosis: Current concepts. *Indian J Orthop*. 2015 Jan-Feb;49(1):28-45.

3. Vardhan H, Tripathy SK, Sen RK, Aggarwal S, Goyal T. Epidemiological Profile of Femoral Head Osteonecrosis in the North Indian Population. *Indian J Orthop*. 2018 Mar-Apr;52(2):140-146.

4. Gayana S, Bhattacharya A, Sen RK, Singh P, Prakash M, Mittal BR. F-18 fluoride positron emission tomography/computed tomography in the diagnosis of avascular necrosis of the femoral head: Comparison with magnetic resonance imaging. *Indian J Nucl Med*. 2016 Jan-Mar;31(1):3-8.

5. Agrawal K, Tripathy SK, Sen RK, Santhosh S, Bhattacharya A. Nuclear medicine imaging in osteonecrosis of hip: Old and current concepts. *World J Orthop*. 2017 Oct 18;8(10):747-753.

6. Deivaraju C, Tripathy SK, Sen RK, Aggarwal S. Efficacy of Core Decompression in Posttraumatic Osteonecrosis of Hip *J Hip Surg* 2017; 01(01): 019-021

7. Hernigou P, Beaujean F. Treatment of osteonecrosis with autologous bone marrow grafting. *Clin Orthop Relat Res*. 2002;405:14-23

8. Gangji V, Hauzeur JP, Matos C, De Maertelaer V, Tounghouz M, Lambermont M. Treatment of osteonecrosis of the femoral head with implantation of autologous bone-marrow cells. A pilot study. *J Bone Joint Surg Am*. 2004; 86-a(6):1153-60

9. Andriolo L, Merli G, Tobar C, Altamura SA, Kon E, Filardo G. Regenerative therapies increase survivorship of avascular necrosis of the femoral head: a systematic review and meta-analysis. *Int Orthop*. 2018;6
10. Gangji V, De Maertelaer V, Hauzeur JP. Autologous bone marrow cell implantation in the treatment of non-traumatic osteonecrosis of the femoral head: Five year follow-up of a prospective controlled study. *Bone*. 2011;49(5): 1005–9
11. Zhao D, Cui D, Wang B, Tian F, Guo L, Yang L, et al. Treatment of early stage osteonecrosis of the femoral head with autologous implantation of bone marrow-derived and cultured mesenchymal stem cells. *Bone*. 2012; 50(1):325–30
12. Sen RK, Tripathy SK, Aggarwal S, Marwaha N, Sharma RR, Khandelwal N. Early results of core decompression and autologous bone marrow mononuclear cells instillation in femoral head osteonecrosis: a randomized control study. *J Arthroplast*. 2012;27(5): 679–86
13. Rastogi S, Sankineani SR, Nag HL, Mohanty S, Shivanand G, Marimuthu K, et al. Intralesional autologous mesenchymal stem cells in management of osteonecrosis of femur: a preliminary study. *Musculoskelet Surg*. 2013;97(3): 223–8
14. Ma Y, Wang T, Liao J, Gu H, Lin X, Jiang Q, et al. Efficacy of autologous bone marrow buffy coat grafting combined with core decompression in patients with avascular necrosis of femoral head: a prospective, double-blinded, randomized, controlled study. *Stem Cell Res Ther*. 2014;5(5):115
15. Mao Q, Wang W, Xu T, Zhang S, Xiao L, Chen D, et al. Combination treatment of biomechanical support and targeted intra-arterial infusion of peripheral blood stem cells mobilized by granulocyte-colony stimulating factor for the osteonecrosis of the femoral head: a randomized controlled clinical trial. *J Bone Miner Res*. 2015;30(4):647–56 .
16. Tabatabaee RM, Saberi S, Parvizi J, Mortazavi SM, Farzan M. Combining Concentrated Autologous Bone Marrow Stem Cells Injection With Core Decompression Improves Outcome for Patients with Early-Stage Osteonecrosis of the Femoral Head: A Comparative Study. *J Arthroplast*. 2015;30(9 Suppl): 11–5
17. Gangji V, Hauzeur JP, Matos C, De Maertelaer V, Tounghouz M, Lambermont M. Treatment of osteonecrosis of the femoral head with implantation of autologous bone-marrow cells. A pilot study. *J Bone Joint Surg Am*. 2004; 86-a(6):1153–60
18. Pepke W, Kasten P, Beckmann NA, Janicki P, Egermann M. Core Decompression and Autologous Bone Marrow Concentrate for Treatment of Femoral Head Osteonecrosis: A Randomized Prospective Study. *Orthop*

- Rev (Pavia). 2016;8(1):6162
19. Gianakos AL, Moya-Angeler J, Duggal S, Zambrana L, Fields KG, Mintz DN, et al. The Efficacy of Bisphosphonates with Core Decompression and Mesenchymal Stem Cells Compared with Bisphosphonates Alone in the Treatment of Osteonecrosis of the Hip: a Retrospective Study. *HSS J*. 2016; 12(2): 137–44
20. Lim YW, Kim YS, Lee JW, Kwon SY. Stem cell implantation for osteonecrosis of the femoral head. *Exp Mol Med*. 2013;45:e61
21. Papakostidis C, Tosounidis TH, Jones E, Giannoudis PV. The role of “cell therapy” in osteonecrosis of the femoral head. A systematic review of the literature and meta-analysis of 7 studies. *Acta Orthop*. 2016;87(1):72–8
22. Hauzeur JP, De Maertelaer V, Baudoux E, Malaise M, Beguin Y, Gangji V. Inefficacy of autologous bone marrow concentrate in stage three osteonecrosis: a randomized controlled double-blind trial. *Int Orthop*. 2017; 7:1429–35
23. Houdek MT, Wyles CC, Collins MS, Howe BM, Terzic A, Behfar A, et al. Stem Cells Combined With Platelet-rich Plasma Effectively Treat Corticosteroid-induced Osteonecrosis of the Hip: A Prospective Study. *Clin Orthop Relat Res*. 2018;476(2):388–97
24. Choudhery MS, Badowski M, Muise A, Pierce J, Harris DT. Donor age negatively impacts adipose tissue-derived mesenchymal stem cell expansion and differentiation. *J Transl Med*. 2014;12:8 .
25. D'Ippolito G, Schiller PC, Ricordi C, Roos BA, Howard GA. Age-related osteogenic potential of mesenchymal stromal stem cells from human vertebral bone marrow. *J Bone Miner Res*. 1999;14(7):1115–22
26. Stenderup K, Justesen J, Clausen C, Kassem M. Aging is associated with decreased maximal life span and accelerated senescence of bone marrow stromal cells. *Bone*. 2003;33(6):919–26 .
27. Aksu AE, Rubin JP, Dudas JR, Marra KG. Role of gender and anatomical region on induction of osteogenic differentiation of human adipose-derived stem cells. *Ann Plast Surg*. 2008;60(3):306–22.
26. Stenderup K, Justesen J, Clausen C, Kassem M. Aging is associated with decreased maximal life span and accelerated senescence of bone marrow stromal cells. *Bone*. 2003;33(6):919–26 .
27. Aksu AE, Rubin JP, Dudas JR, Marra KG. Role of gender and anatomical region on induction of osteogenic differentiation of human adipose-derived stem cells. *Ann Plast Surg*. 2008;60(3):306–22.
28. Baer PC, Geiger H. Adipose-derived mesenchymal stromal/stem cells: tissue localization, characterization, and heterogeneity. *Stem Cells Int*. 2012;2012: 812693
29. Wyles CC, Houdek MT, Crespo-Diaz

- RJ, Norambuena GA, Stalboerger PG, Terzic A, et al. Adipose-derived Mesenchymal Stem Cells Are Phenotypically Superior for Regeneration in the Setting of Osteonecrosis of the Femoral Head. *Clin Orthop Relat Res*. 2015;473(10):3080–90.
30. Lee JS, Lee JS, Roh HL, Kim CH, Jung JS, Suh KT. Alterations in the differentiation ability of mesenchymal stem cells in patients with nontraumatic osteonecrosis of the femoral head: comparative analysis according to the risk factor. *J Orthop Res*. 2006;24(4):604–9.
31. Suh KT, Kim SW, Roh HL, Youn MS, Jung JS. Decreased osteogenic differentiation of mesenchymal stem cells in alcohol-induced osteonecrosis. *Clin Orthop Relat Res*. 2005;431:220–5.
32. Houdek MT, Wyles CC, Packard BD, Terzic A, Behfar A, Sierra RJ. Decreased Osteogenic Activity of Mesenchymal Stem Cells in Patients With Corticosteroid-Induced Osteonecrosis of the Femoral Head. *J Arthroplast*. 2016;31(4):893–8.
33. Wang BL, Sun W, Shi ZC, Lou JN, Zhang NF, Shi SH, et al. Decreased proliferation of mesenchymal stem cells in corticosteroid-induced osteonecrosis of femoral head. *Orthopedics*. 2008;31(5):444.
34. Lee HJ, Kang KS, Kang SY, Kim HS, Park SJ, Lee SY, et al. Immunologic properties of differentiated and undifferentiated mesenchymal stem cells derived from umbilical cord blood. *J Vet Sci*. 2015;17(3):289–97.
35. Cai J, Wu Z, Huang L, Chen J, Wu C, Wang S, et al. Cotransplantation of bone marrow mononuclear cells and umbilical cord mesenchymal stem cells in avascular necrosis of the femoral head. *Transplant Proc*. 2014;46(1): 151–5.
36. Chen C, Qu Z, Yin X, Shang C, Ao Q, Gu Y, et al. Efficacy of umbilical cord-derived mesenchymal stem cell-based therapy for osteonecrosis of the femoral head: A three-year follow-up study. *Mol Med Rep*. 2016;14(5):4209–15.
37. Muschler GF, Boehm C, Easley K. Aspiration to obtain osteoblast progenitor cells from human bone marrow: the influence of aspiration volume. *J Bone Joint Surg Am*. 1997;79(11):1699–709.
38. Hernigou P, Poignard A, Beaujean F, Rouard H. Percutaneous autologous bone-marrow grafting for nonunions. Influence of the number and concentration of progenitor cells. *J Bone Joint Surg Am*. 2005;87(7):1430–7.
39. Hernigou P, Trousselier M, Roubineau F, Bouthors C, Chevallier N, Rouard H, et al. Stem Cell Therapy for the Treatment of Hip Osteonecrosis: A 30-Year Review of Progress. *Clin Orthop Surg*. 2016;8(1):1–8.
40. Hernigou P, Poignard A, Zilber S, Rouard H. Cell therapy of hip osteonecrosis with autologous bone marrow grafting. *Indian J Orthop*. 2009;43(1):40–5.

41. Aarvold A, Smith JO, Tayton ER, Jones AM, Dawson JI, Lanham S, et al. From bench to clinic and back: skeletal stem cells and impaction bone grafting for regeneration of bone defects. *J Tissue Eng Regen Med*. 2014;8(10):779–86
42. Aarvold A, Smith JO, Tayton ER, Jones AM, Dawson JI, Lanham S, et al. A tissue engineering strategy for the treatment of avascular necrosis of the femoral head. *Surgeon*. 2013;11(6):319–25
43. Kang JS, Moon KH, Kim BS, Kwon DG, Shin SH, Shin BK, et al. Clinical results of auto-iliac cancellous bone grafts combined with implantation of autologous bone marrow cells for osteonecrosis of the femoral head: a minimum 5-year follow-up. *Yonsei Med J*. 2013;54(2):510–5
44. Aoyama T, Goto K, Kakinoki R, Ikeguchi R, Ueda M, Kasai Y, et al. An exploratory clinical trial for idiopathic osteonecrosis of femoral head by cultured autologous multipotent mesenchymal stromal cells augmented with vascularized bone grafts. *Tissue Eng B Rev*. 2014;20(4):233–42
45. Zhao D, Liu B, Wang B, Yang L, Xie H, Huang S, et al. Autologous bone marrow mesenchymal stem cells associated with tantalum rod implantation and vascularized iliac grafting for the treatment of end-stage osteonecrosis of the femoral head. *Biomed Res Int*. 2015;240506
46. Yamasaki T, Yasunaga Y, Ishikawa M, Hamaki T, Ochi M. Bone-marrow-derived mononuclear cells with a porous hydroxyapatite scaffold for the treatment of osteonecrosis of the femoral head: a preliminary study. *J Bone Joint Surg Br*. 2010;92(3):337–41
47. Liu Y, Liu S, Su X. Core decompression and implantation of bone marrow mononuclear cells with porous hydroxylapatite composite filler for the treatment of osteonecrosis of the femoral head. *Arch Orthop Trauma Surg*. 2013;133(1):125–33
48. Pak J. Autologous adipose tissue-derived stem cells induce persistent bone-like tissue in osteonecrotic femoral heads. *Pain physician*. 2012;15(1):75–85
49. Pilge H, Bittersohl B, Schneppendahl J, Hesper T, Zilkens C, Ruppert M, et al. Bone Marrow Aspirate Concentrate in Combination With Intravenous Iloprost Increases Bone Healing in Patients With Avascular Necrosis of the Femoral Head: A Matched Pair Analysis. *Orthop Rev*. 2016;8(4):6902

#### Orthobiologics in the treatment of Early Osteoarthritis - A Systematic Review

1. Schminke B, Miosge N. Cartilage repair in vivo: the role of migratory progenitor cells. *Curr Rheumatol Rep*. 2014 Nov;16(11):461.
2. Allen KD, Golightly YM. State of the

- evidence. *Curr Opin Rheumatol*. 2015;27(3):276-83.
3. Kon E, Filardo G, Drobic M, Madry H, Jelic M, et al. (2012) Nonsurgical management of early knee osteoarthritis. *Knee Surg Sports Traumatol Arthrosc* 20: 436-449
  4. Aggarwal A (2015) Emergence of Orthobiologics as a Novel Therapeutic Modality for Osteoarthritis of Knee. *Rheumatology (Sunnyvale)* 5:159. doi: 10.4172/2161-1149.1000159
  5. Arnoczky SP, Fu FH, Mishra AK. Platelet-rich plasma: Clarifying the issues. *JAAOS*, Volume 18, Issue 7, July 2010.
  6. Margolis DJ, Kantor J, Santanna J, Strom BL, Berlin JA. Effectiveness of Platelet Release for the Treatment of Diabetic Neuropathic Foot Ulcers. *Diabetes Care* 2001 Mar; 24(3): 483-488.
  7. Marx RE. Platelet-rich plasma: evidence to support its use. *J Oral Maxillofac Surg*. 2004 Apr;62(4):489-96.
  8. Sampson S, Reed M, Silvers H, Meng M, Mandelbaum B (2010) Injection of platelet-rich plasma in patients with primary and secondary knee osteoarthritis: a pilot study. *Am J Phys Med Rehabil* 89: 961-969.
  9. Wang-Saegusa A, Cugat R, Ares O, Seijas R, Cuscó X, et al. (2011) Infiltration of plasma rich in growth factors for osteoarthritis of the knee short-term effects on function and quality of life. *Arch Orthop Trauma Surg* 131: 311-317. 13.
  10. Kon E, Mandelbaum B, Buda R, Filardo G, Delcogliano M, et al. (2011) Platelet-rich plasma intra-articular injection versus hyaluronic acid viscosupplementation as treatments for cartilage pathology: from early degeneration to osteoarthritis. *Arthroscopy* 27: 1490-1501.
  11. Spaková T, Rosocha J, Lacko M, Harvanová D, Gharaibeh A (2012) Treatment of knee joint osteoarthritis with autologous platelet-rich plasma in comparison with hyaluronic acid. *Am J Phys Med Rehabil* 91: 411-417.
  12. Sánchez M, Fiz N, Azofra J, Usabiaga J, Aduriz Recalde E, et al. (2012) A randomized clinical trial evaluating plasma rich in growth factors (PRGFEndoret) versus hyaluronic acid in the short-term treatment of symptomatic knee osteoarthritis. *Arthroscopy* 28: 1070-1078.
  13. Anitua E, Sánchez M, Aguirre JJ, Prado R, Padilla S, et al. (2014) Efficacy and safety of plasma rich in growth factors intra-articular infiltrations in the treatment of knee osteoarthritis. *Arthroscopy* 30: 1006-1017.
  14. Dai WL, Zhou AG, Zhang H, Zhang J. Efficacy of Platelet-Rich Plasma in the Treatment of Knee Osteoarthritis: A Meta-

- analysis of Randomized Controlled Trials. *Arthroscopy*. 2017 Mar;33(3):659-670.e1. doi: 10.1016/j.arthro.2016.09.024.
15. Martini LI, Via AG, Fossati C, Randelli F, Randelli P, Cucchi D. Single Platelet-Rich Plasma Injection for Early Stage of Osteoarthritis of the Knee. *Joints*. 2017 Jun 5;5(1):2-6. doi: 10.1055/s-0037-1601405.
  16. Di Martino A, Di Matteo B, Papio T, Tentoni F, Selleri F, Cenacchi A, Kon E, Filardo G. Platelet-Rich Plasma Versus Hyaluronic Acid Injections for the Treatment of Knee Osteoarthritis: Results at 5 Years of a Double-Blind, Randomized Controlled Trial. *Am J Sports Med*. 2018 Dec 13;363546518814532.
  17. Wakitani S, Imoto K, Yamamoto T, Saito M, Murata N, et al. (2002) Human autologous culture expanded bone marrow mesenchymal cell transplantation for repair of cartilage defects in osteoarthritic knees. *Osteoarthritis Cartilage* 10: 199-206.
  18. Centeno CJ, Busse D, Kisiday J, Keohan C, Freeman M, et al. (2008) Increased knee cartilage volume in degenerative joint disease using percutaneously implanted, autologous mesenchymal stem cells. *Pain Physician* 11: 343-353.
  19. Emadedin M, Aghdami N, Taghiyar L, Fazeli R, Moghadasali R, et al. (2012) Intra-articular injection of autologous mesenchymal stem cells in six patients with knee osteoarthritis. *Arch Iran Med* 15: 422-428.
  20. Orozco L, Munar A, Soler R, Alberca M, Soler F, et al. (2013) Treatment of knee osteoarthritis with autologous mesenchymal stem cells: a pilot study. *Transplantation* 95: 1535-1541.
  21. Kim JD, Lee GW, Jung GH, Kim CK, Kim T, et al. (2014) Clinical outcome of autologous bone marrow aspirates concentrate (BMAC) injection in degenerative arthritis of the knee. *Eur J Orthop Surg Traumatol* 24: 1505-1511.
  22. Chahla J, Dean CS, Moatshe G, Pascual-Garrido C, Serra Cruz R, LaPrade RF. Concentrated Bone Marrow Aspirate for the Treatment of Chondral Injuries and Osteoarthritis of the Knee: A Systematic Review of Outcomes. *Orthop J Sports Med*. 2016 Jan 13;4(1): 2325967115625481.
  23. Moatshe G, Morris ER, Cinque ME, Pascual-Garrido C, Chahla J, Engebretsen L, Laprade RF. Biological treatment of the knee with platelet-rich plasma or bone marrow aspirate concentrates. *Acta Orthop*. 2017 Dec;88(6):670-674. doi: 10.1080/17453674.2017.1368899.
  24. Themistocleous GS, Chloros GD, Kyrantzoulis IM, Georgokostas IA, Themistocleous MS, Papagelopoulos PJ, Savvidou OD. Effectiveness of a single

- intra-articular bone marrow aspirate concentrate (BMAC) injection in patients with grade 3 and 4 knee osteoarthritis. *Heliyon*. 2018 Oct 18;4(10):e00871.
25. Bentley G, Minas T. Treating joint damage in young people. *BMJ*. 2000;320:1585–1588.
  26. Gooding CR, Bartlett W, Bentley G, Skinner JA, Carrington R, Flanagan A. A prospective, randomised study comparing two techniques of autologous chondrocyte implantation for osteochondral defects in the knee: Periosteum covered versus type I/III collagen covered. *Knee*. 2006;13:203–210.
  27. Basad E, Ishaque B, Bachmann G, Stürz H, Steinmeyer J: Matrix-induced autologous chondrocyte implantation versus microfracture in the treatment of cartilage defects of the knee: a 2-year randomised study. *Knee Surg Sports Traumatol Arthrosc* 2010, 18:519-527.
  28. Erggelet C, Sittinger M, Lahm A: The arthroscopic implantation of autologous chondrocytes for the treatment of full thickness cartilage defects of the knee joint. *Arthroscopy* 2003, 19:108-110
  29. Della Villa S, Kon E, Filardo G, Ricci M, Vincentelli F, Delcogliano M, Marcacci M: Does intensive rehabilitation permit early return to sport without compromising the clinical outcome after arthroscopic autologous chondrocyte implantation in highly competitive athletes? *Am J Sports Med* 2010, 38:68-77.
  30. Choi et al., Gel-type autologous chondrocyte (Chondron™) implantation for treatment of articular cartilage defects of the knee *BMC Musculoskeletal Disorders* 2010, 11:103
  31. Peterson, L., Vasiliadis, H. S., Brittberg, M., & Lindahl, A. (2010). Autologous Chondrocyte Implantation: A Long-term Follow-up. *The American Journal of Sports Medicine*, 38(6), 1117–1124.
  32. A. Viste, M. Piperno, R. Desmarchelier, S. Grosclaude, B. Moyon, M.H. Fessy, Autologous chondrocyte implantation for traumatic full-thickness cartilage defects of the knee in 14 patients: 6-year functional outcomes, *Orthop. Traumatol. Surg. Res.* 98 (2012) 737–743,
  33. Minas T, Von Keudell A, Bryant T, Gomoll AH. The John Insall Award: A minimum 10-year outcome study of autologous chondrocyte implantation. *Clin Orthop Relat Res*. 2013;472(1):41-51.
  34. Mistry H, Connock M, Pink J, et al. Autologous chondrocyte implantation in the knee: systematic review and economic evaluation. Southampton (UK): NIHR Journals Library; 2017 Feb.
  35. Jungmann, P.M., Gersing, A.S., Baumann, F. et al. *Knee Surg Sports Traumatol Arthrosc* (2018).